

## Utility of Placental Umbilical Cord Blood in Autoimmune and Degenerative Disorders

Maimuna Khatoon<sup>1</sup>, Jyoti Bindal<sup>1</sup>, Dharmesh Chandra Sharma<sup>2\*</sup>,  
Prakriti Gupta<sup>2</sup>, Ashok Singh Tomar<sup>2</sup>, Khozema Saify<sup>3</sup> and Rakesh Gupta<sup>4</sup>

<sup>1</sup>Department of Obstetrics and Gynaecology, Gajra Raja Medical College, Gwalior, India.

<sup>2</sup>Department of Pathology, Blood Bank, Gajra Raja Medical College, Gwalior, India.

<sup>3</sup>Dr. Khozema Saify Clinic, Thatipur, Gwalior, India.

<sup>4</sup>K. V. M. Eye Hospital, Kampoo, Gwalior, India.

### Authors' contributions

*This work was carried out in collaboration between all authors. Authors MK, JB and DCS designed the study, performed the statistical analysis, wrote the protocol, and wrote the first draft of the manuscript. Authors PG and AST managed the analyses of the study. Authors KS and RK managed the literature searches and clinical aspect of the study. All authors read and approved the final manuscript.*

### Article Information

DOI: 10.9734/IBRR/2018/45260

#### Editor(s):

(1) Dr. Mehmet Sonmez, Professor, Department of Haematology, School of Medicine, Karadeniz Technical University, Turkey.

#### Reviewers:

(1) Panagiotis Tsikouras, Democritus University of Thrace Greece, Greece.

(2) Livia Garcia Bertolacci-Rocha, Universidade Federal de Goiás, Brasil.

(3) Dario Siniscalco, University of Campania, Naples, Italy.

Complete Peer review History: <http://www.sciedomains.org/review-history/27333>

Original Research Article

Received 12 September 2018

Accepted 15 November 2018

Published 21 November 2018

### ABSTRACT

**Background:** Umbilical cord blood is whole human blood (60 to 80 ml) that remains in the placenta and umbilical cord after childbirth; generally considered as a medical waste. It is a rich source of stem cells, growth factor, cytokines, etc., and, can be collected, stored and utilized in the treatment of incurable diseases.

**Aims and Objects:** The aim of the present study is to establish the fact that placental umbilical cord whole blood is a safe alternative to adult blood and to assess its utility in degenerative and autoimmune disease along with its hematological parameters.

**Materials and Methods:** It is a prospective two year study (From September 2016 to August 2018) of 250 umbilical cord whole blood transfusions in autoimmune and degenerative disorders at Gajra Raja Medical College, Gwalior, India. Follow up of patients was done up to 3 months and data was collected and analyzed statistically by frequency distribution and percentage proportion.

\*Corresponding author: E-mail: Sharmadrdharmesh@gmail.com, dr\_dharmesh\_sharma@yahoo.com;

**Results:** A total of 250 units meeting the inclusion and exclusion criteria were transfused to 99 preregistered patients; Vitiligo 61 (159 transfusions), Thalassemia 15 (30), Retinitis Pigmentosa 9 (23), Geriatric Disorders 9 (24), Aplastic anemia 4 (9) and High Myopia 1 (5). Out of 250 transfusions, in one case (0.4%) adverse event was reported. Outcome of transfusion reveals; In Vitiligo –regimentation in affected area, Thalassemia-reduction in frequency of transfusions, Retinitis Pigmentosa- improvement in vision area, Geriatric patients- sense of well being, Aplastic anemia-prolonged survival and High Myopia-improvement in vision area.

**Conclusion:** Umbilical cord blood is safe and genuine alternative of adult blood. It is effective in degenerative and autoimmune diseases. It should not be discarded as medical waste and utilized judiciously in the human well being.

*Keywords: Umbilical Cord Blood (UCB); transfusion; stem cell; cytokines and growth factor.*

## 1. INTRODUCTION

The role of the blood and its components is increasing day by day in the allopathic medicine, not only because of its requirement in accidents, surgeries, and anemia cases but also it has a therapeutic value in so many diseases. Till date, there has been no complete substitute for human blood [1]. What so ever on trial as substitutes for blood are not fulfilling the desired parameters? As far as artificial blood is concerned, no truthfully safe and efficient artificial blood product is currently marketed [2]. Here, we can say that the term “artificial blood” is really a misnomer. The complexity of blood is far too great to allow for absolute duplication in a laboratory [3]. So we are looking for the optional source of human blood; that can be umbilical cord blood (UCB) or cadaveric blood which can be saved and utilized [4]. Previously, it was a general practice that after birth placenta and its cord was discarded as a medical waste [5]. Placenta and its cord has 80 to 120 ml precious human blood, a rich source of stem cells, so it can be saved, stored and used as a replacement of adult whole human blood as well as a source of virgin stem cells [6]. Cord blood collection is done by venipuncture of an umbilical cord and blood flows by gravity into a citrate phosphate dextrose (CPD) bag. Collection of UCB is similar to the manner in which a conventional adult blood donation is collected and it is painless [7]. Human leukocyte antigen (HLA) on umbilical cord blood stem cells is under developed, so it has a better tolerance for HLA mismatching in comparison with adult hematopoietic stem cell [8]. Stem cells in UCB are 0.01% of the total cellular content, whereas, it is 0.1% and 0.001% in bone marrow and peripheral blood respectively. So here it is wise not to discard 99.9% UCB Cells for the sake of 0.01% stem cells [9]. UCB has higher cellular content as compared to adult human blood. Hemoglobin in UCB is 20g/ cu mm as compared

to 14.4 g/cu mm in adult blood with 70% fetal haemoglobin, platelets are 750000 against 250000 for each cu mm of adult blood and leukocyte count of 24000 as a detriment to 6500-10,500 cells/ cu mm in adult blood. Due high fetal haemoglobin content of UCB it carries 60% more oxygen than adult haemoglobin [10].

The first attempt to use UCB as a substitute to adult blood was made in 1939, by Halbrecht [11,12]. In India, researchers were successfully able to transfuse UCB without jeopardising the patients' safety [13]. Studies were conducted and UCB transfusion was used to treat autoimmune diseases and anaemia [14].

Umbilical cord blood is wealthy in fetal haemocomponents and hence can be a perfect and elective source for both autologous and allogenic blood transfusion in new conceived babies [15, 16].

Cord RBCs are unique cells that differ from adult RBCs in membrane composition and biophysical properties [17,18], haemoglobin structure [17-20], metabolism and enzymatic profile [21,22].

On account of a healthy neonate, UCB does not contain any obtained antibodies. Erythrocyte articulation of Antigen A and B is to extremely low and is regularly around 3% to 7%. For minor blood groups like Kelly and Luther, the antigenic articulation is nearly undetectable [23]. In this way UCB is considered safe for transfusion. Therefore, the present study is designed and carried out to discern the utility of UCB in various diseases and geriatric disorders.

## 2. MATERIALS AND METHODS

It is a prospective two year study (September 2016 to August 2018) of 250 UCB transfusions in autoimmune and degenerative disorders (i.e.

mainly vitiligo, aplastic anemic, thalassemia, retinitis pigmentosa and other ophthalmic degenerative diseases, and geriatric patients). UCB was collected in CPD bags of 100 ml capacity (HLL Life-care Limited) with all aseptic precautions from normal healthy deliveries conducted in Labor Room, Obstetrics and Gynecology Department and transported to blood bank, J. A. Hospital Gwalior. Blood grouping and Rh typing, TTIs status of blood unit and, DCT (Direct Coombs Test) and ICT (Indirect Coombs Test) of blood were done in blood bank. ABO and Rh blood grouping, DCT and ICT of the UCB sample was done by conventional tube methods and gel technology (column agglutination; Tulip Diagnostics). TTIs test of UCB units was done by Elisa Method using Elisa reader (Robonik and Elisa kit of J Mitra & co. Pvt. Ltd). Along with collection of UCB, out of 250 cases, in 100 cases we were able to collect 3ml blood from the cord separately in EDTA vial for complete haemogram. Complete haemogram was performed on 5 part haematology analyser (MINDRAY –MODEL BC-5300).

Blood units fit for transfusion, after cross match were transfused to pre registered patients for the study. Patients were registered either on request of clinicians who had an opinion that their patients will be benefited by the transfusion of UCB or to those patients who were willing to

have UCB transfusion as a prospective treatment for their illness.

**Inclusion criteria:** UCB was collected only from patients who gave legal consent for the procedure. UCB was collected from normal deliveries with a visibly healthy placenta and fulfilling all aseptic criteria.

**Exclusion criteria:** UCB from diseased or anaemic placenta was not collected.

Collected Units positive for HIV I &II, HbsAg, HCV, VDRL and MP were discarded. Unit's positive for ICT and DCT were also discarded. Quantity of blood collected less than 60 ml was unfit for transfusion.

Cord blood was transfused at J.A. Groups of Hospitals and at other hospitals of Gwalior under medical supervision with proper documentation. After completion of transfusion, follow-up of patients were done in accordance with the treating doctor every 15 days up to 3 months.

### 3. RESULTS

In the present study, Out of the 269 UCB collected, 19 units were found unfit and discarded, details of discarded units are depicted in Fig. 1.

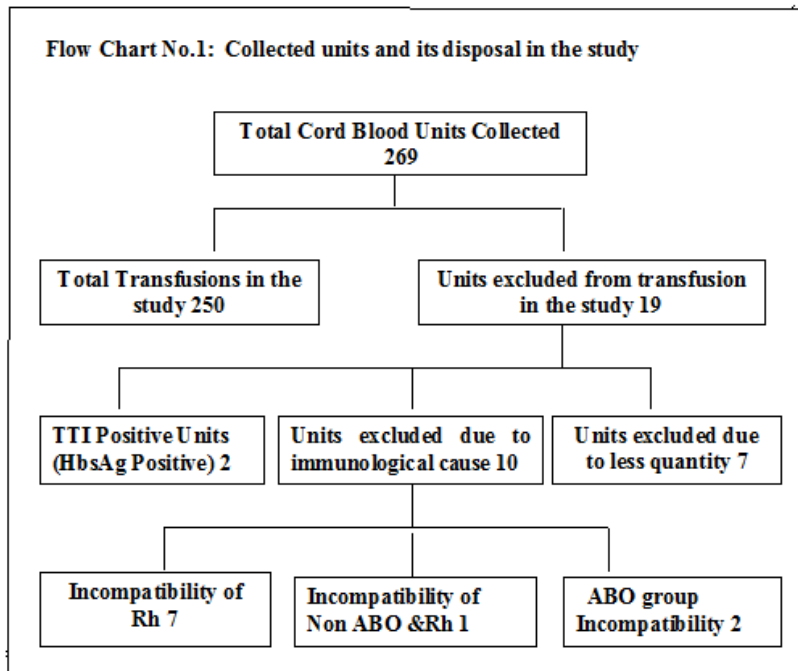


Fig. 1. Flowchart depicting the collected and discarded UCB units

ABO and Rh distribution of UCB units in the study are depicted in Fig. 2.

Out of 250 UCB units accepted for transfusion, 100 randomly selected samples were subjected to haematological analysis. Findings are summarised in Table 1.

Quantity of blood varied from 60 to 100 ml with the mean of  $70.66 \pm 12.74SD$ . Average transfusion per patient in present study was 2.53: minimum one and maximum 5 transfusions.

In the study, total number of patients enrolled was 99 in whom 250 transfusions were given. Age of the patients range was from less than 1 year to 68 years with an average age of  $28.25 \pm 20.22SD$ .

Out of 99 Patients, 52 (52.53%) were male and 47 (47.47%) were female. ABO and Rh-D distribution of 99 patients in the present study was; A: 20, B: 34, O: 16 and AB: 7. Out of total 99 patients Rh-D status of patients; 95 were Rh positive and 4 patients were Rh negative.

Transfusion adverse reaction was noted only in 1 case (0.4%). Reaction was febrile non haemolytic transfusion reaction (FNHTR) which was due to platelet and leukocyte content of cord blood. This was managed symptomatically.

Disease wise distribution of patients, number of transfusions and clinical outcome is summarised in Table 2.

Satisfactory recovery in patients of vitiligo is shown in following Figs. 3 & 4.

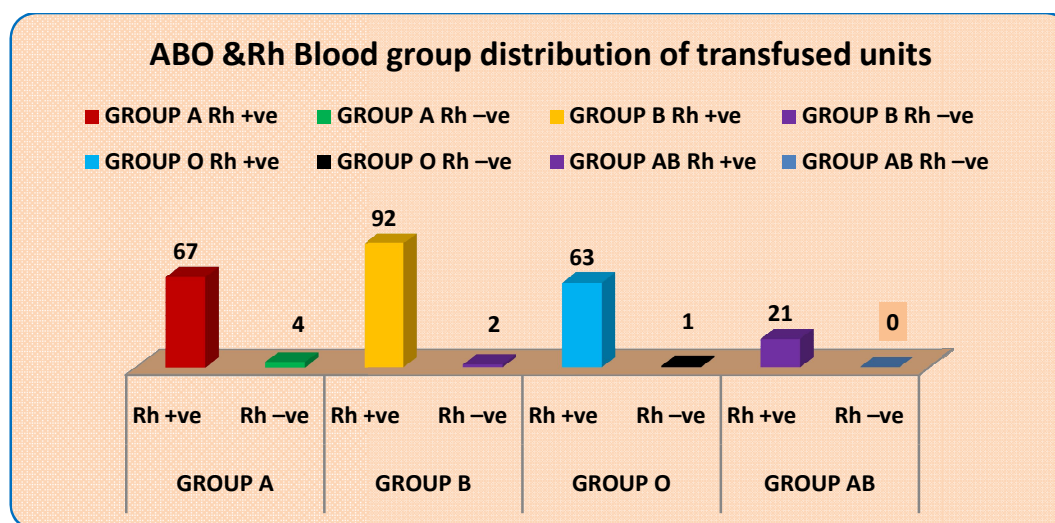


Fig. 2. ABO and Rh distribution of UCB units in the study

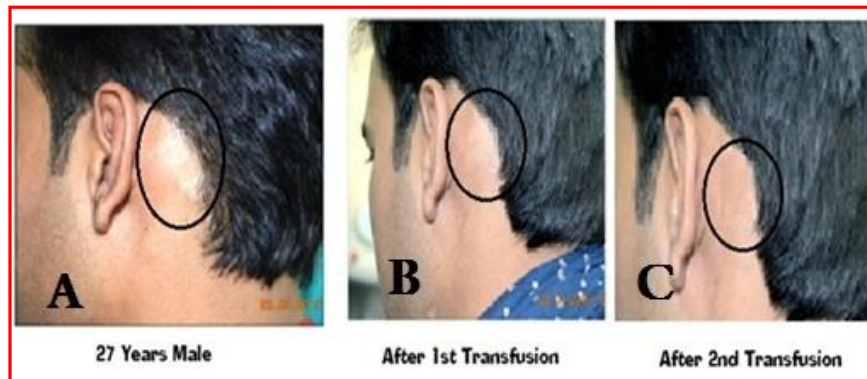Table 1. Haematological parameters of 100 UCB units

Parameters	Mean $\pm$ Standard Deviation	Range
WBC	$12.0 \pm 2.47 \times 10^3/\text{cumm}$	8- 17 x $10^3/\text{cumm}$
RBC	$4.4 \pm 0.44 \times 10^6/\text{cumm}$	3.2- 5.9 x $10^6/\text{cumm}$
Platelet Count	$217.0 \pm 59.25 \times 10^3/\text{cumm}$	$120 \pm 350 \times 10^3/\text{cumm}$
HGB	$14.20 \pm 0.79 \text{ g/dl}$	12.63-16.8 g/dl
HCT (%)	$43.23 \% \pm 2.67\%$	37-50 %
MCV (fl)	$98.36 \pm 4.6\text{fl}$	93.4-110.2 fl
MCH (pg)	$38.22 \pm 1.65 \text{ pg}$	30.2-36 pg
MCHC (g/dl)	$32.88 \pm 1.03 \text{ g/dl}$	31.5-34.7 g/dl
<b>Differential WBC</b>		
Polymorphs	$44.77 \pm 8.27 \%$	22- 60 %
Lymphocytes	$47.14 \pm 6.7\%$	40-72%
Monocytes	$4.67 \pm 2.10 \%$	2-10 %
Eosinophils	$3.14 \pm 1.84\%$	2-10 %
Basophils	$1.05 \pm 1.65\%$	0-6%

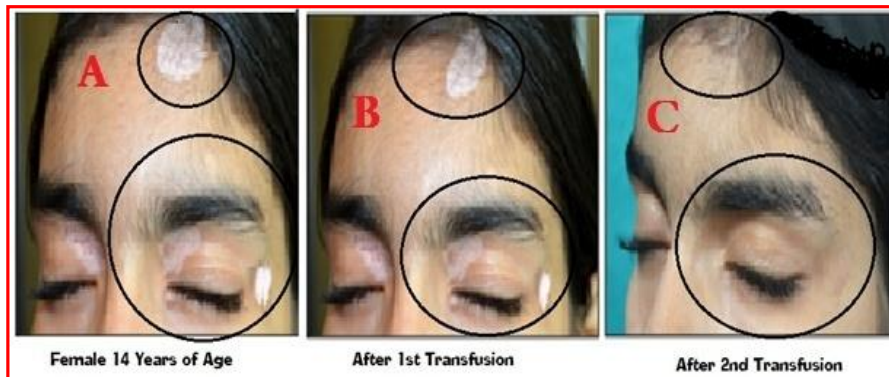**Table 2. Disease wise distribution of patients, number of transfusions and clinical outcome**

Sino.	Diagnosis	No. of patients	No. of transfusions	Average transfusions /patient	Clinical outcome
1	Vitiligo	61	159	2.60	Re-pigmentation in affected area Good response <sup>†</sup> - 30% Average response <sup>#</sup> - 50% No response- 20% Initiation of re-pigmentation in old, chronic, non-responding patients
2	Thalassemia	15	30	2	Reduction in frequency of transfusion Haemoglobin level of patients increased from 0.5 to 1 gm/dl Interval between two transfusions increased by 11± 3 days.
3	Aplastic Anemia	4	9	2.25	Prolonged survival UCB transfusion 3 to 4 time / year in 27Y/M Hb maintained at 8gm/dl platelet count 35-40 x 10 <sup>3</sup> / cu mm.
4	Retinitis Pigmentosa	9	23	2.55	Improvement in vision area 20-30% with minimum two transfusions
5	Geriatric Disorders	9	24	2.66	Sense of well being and ride of common geriatric sign & symptoms
6	High Myopia	1	5	5	Improvement in vision area

\* 2/3<sup>rd</sup> re-pigmentation in affected area, # half re-pigmentation in affected area



**Fig. 3. (A) Vitiligo mark behind the left Ear. (B) Recovery after First UCB transfusion. (C) Complete recovery after 2<sup>nd</sup> UCB transfusion**



**Fig. 4. (A) Multiple Vitiligo mark over face. (B) Recovery after First transfusion of UCB. (C) Almost complete recovery after 2<sup>nd</sup> UCB transfusion**

#### **4. DISCUSSION**

Allogenic UCB transfusion was first reported in the 1930s, before the advent of modern blood transfusion services [11,12]. Then, most researches and clinical activities relating to UCB have limited up to autologous UCB transfusion in preterm neonates and utility of UCB stem cells in bone marrow transplants. Transfusion of UCB as a therapy for various diseases has not been extensively studied. Use of UCB to ameliorate symptoms in malignancies, autoimmune disorders, anaemia, geriatric disorders and leprosy have been reported in few studies, and did not reveal any adverse event due to UCB transfusion [23-28].

Status of UCB as a safe alternative to whole human adult blood is further strengthened by the results of our study, wherein 0.4% (only one case) of FNHTR was reported, a most commonly encountered adverse event of blood transfusion.

Variability has been observed in reporting the haematological parameters of UCB in various studies. Agrawal N in her study of "Transfusion of Placental Umbilical Cord Whole Blood (Rich in Stem Cells) in Transfusion Dependent Patients and to Assess Its Outcome" reported haemoglobin of cord blood varying from 16.2 to 20.2 g/dl against the average adult haemoglobin 14.4 g/dl with the average 72 gm % of fetal haemoglobin [4]. Bhattacharya N reported mean haemoglobin concentration 18- 12.4 g/dL and 18 - 14.8 g/dl in his two different studies [13,29]. Noguera NI et al. [30] reported haemoglobin levels of 14.4 - 16.6 g/dl. In our study, haemoglobin range was found to be 12.63-16.8 g/dl.

Despite the comparable values of haemoglobin in UCB with adult whole blood in our study, it has been found to be effective in thalassemia patients because of the presence of fetal haemoglobin in UCB. Of the 15 thalassemic patients in our study, receiving an average of 2 transfusions/ patient, the haemoglobin level increased from 0.5 to 1.0 gm/dl. Haemoglobin estimation was repeated 15 days after transfusion where there was marked secondary rise in the haemoglobin concentration which may be due to cytokine stimulation effect of cord blood on the host bone marrow. In a similar study of Bhattacharya N on thalassemic patients there was an increase in haemoglobin from 0.6 to 1.2 gm/dl and secondary rise in haemoglobin seen after 7 days of transfusion [31]. Due to higher O<sub>2</sub>

carrying capacity of umbilical cord whole blood, less number of transfusions were needed in our patients. This might be helpful in reducing iron overload and preventing heart failure in these chronic transfusion dependent patients.

In the patient group of aplastic anemia (total case- 4) in our study, follow up could be done of 1 case only. The said patient received 4 transfusions of UCB, has a satisfactory recovery from the disease and still in our treatment since 2 years. His Hb is maintained at 8gm/dl and platelet count at 35-40 x 10<sup>3</sup> / cu mm with UCB transfusion. Presently he requires approximately two transfusions of UCB or packed RBCs / year for anemia correction. In a study of haematological malignancies done by Bhattacharya N [32], he gave multiple transfusions to six malignant cases and he reported change in CD34 level in peripheral blood. One of their cases showed a frequent steep rise up to 99% and a sustained high level of CD34 with clinical remission of disease. However, we have not included haematological malignancy in our study. From above observation on the aplastic anemia case, it is our presumption that improvement in the patient condition may be either be because of stimulation of existing bone marrow by growth factors and cytokines or acceptance of transfused stem cells by host.

Encouraged by results of our study in vitiligo patients, we hypothesise that growth factors, cytokines and some unknown factor/ proteins in the UCB work for regeneration of melanocytes or transfused stem cells richly present in UCB implant at vitiligo sites and get converted in melanocytes. Dramatic regeneration of melanocytes is seen in 61 vitiligo patients in our study. Repigmentation was observed in 2/3<sup>rd</sup> to half of the affected area in 80% of patients and initiation of pigmentation was seen in chronic non responders on follow up. Our results strengthen the observations of study conducted at our institute in 2016 by Agarwal N [4]. To best of our knowledge, no one else has transfused UCB to the vitiligo patients as treatment apart from our institute.

Similarly in our 9 case of retinitis pigmentosa which received 23 UCB transfusions with the interval of 1 month all the patients had improvement in their vision by 30% to 40%. There was no other study reported for the same, except for the study of Agawam N who in our institute reported the improvement in one case

(the only case in the study) of retinitis pigmentosa after UCB transfusion [4]. We suggest conduction of a study with higher case numbers of vitiligo and retinitis pigmentosa to bring UCB transfusion in forefront as a prospective treatment, since both of these diseases have been deemed incurable:

“There are no cures for vitiligo and retinitis pigmentosa only several supportive treatment options are available” [33,34]

Due to increasing geriatric population all over the world and an arising need for advent of regenerative medicine, newer modalities are being investigated for a targeted approach. Old age is marked with loss of renewal of stem cell niche in body which in turn affects the tissue repair. Therefore, stem cell therapy has come up as potential candidates for regenerative medicine. Cord blood is richer in stem cells constituting 0.01% of cellular population as compared to adult peripheral blood which has 0.001% of stem cells [31]. Promising results are reported by Jesse Karmazin, an entrepreneur who launched a clinical trial on the potential of “young blood” through his startup Ambrosia. He reported that within a month, most participants “see improvements” from the one-time infusion of a two-liter bagful of plasma. With an intention to alleviate the symptoms of old age, we transfused 24 UCB units to 9 geriatric patients with the average of 2.66 transfusions /patient. All the patients reported satisfactory response with UCB with improvement in lack of interest in work, tiredness, fatigue and general weakness. Control over their geriatric diseases like; asthma, diabetes, thyroid, etc was also achieved. With the results of our study, we hypothesise that UCB proves to be a better substitute to “young blood” to treat geriatric disorders and suggest larger clinical trials or studies to prove the same. In our study we could enroll only one patient of high myopia, to whom 5 transfusions were given. We observed a subjective finding in the patient; his vision was improved from 6/60 to 6/24 (from 1<sup>st</sup> row to 3<sup>rd</sup> row of Snellen chart) in both the eyes. So, we can say there is a hope for high myopic patient by the treatment of UCB transfusion.

## 5. CONCLUSION

The UNICEF estimates that averages of 3.53 lakhs babies are born each day around the world. If per delivery placenta and umbilical cord have on an average 70 ml blood then total

blood; 3.53 lakh X 0.07 liter =2.45 lakh liter. This precious human cord blood i.e. 2.45 lakh liter/day, if not utilised, is a medical waste; so it is not wise to waste the precious human cord blood. Umbilical cord blood is safe and genuine alternative of adult blood. It is effective in the treatment of degenerative and autoimmune diseases. UCB is also useful in neonates (less quantity of blood is required), chronically transfused patients and a hope for geriatric persons. By our study and previous studies, it is concluded that there is no chance of graft versus host disease by UCB transfusion. Here, we are recommending that it should not be discarded as medical waste and utilised judiciously in the interest of human well being.

## CONSENT

All authors declare that written informed consent was obtained from the donor and recipient of UCB. Consent was taken from appropriate authority for publication of this research work.

## ETHICAL APPROVAL

All authors hereby declare that all experiments have been examined and approved by the appropriate ethics committee of Gajra Raja Medical College, Gwalior, India, as well as appraisal committee, department of health, government of Madhya Pradesh India. This work was performed in accordance with the ethical standards laid down in the 1964 Declaration of Helsinki.

## COMPETING INTERESTS

Authors have declared that no competing interests exist.

## REFERENCES

1. Agarwal SP. National voluntary blood donation day - message of the secretary general; 2012. Available:<http://www.indianredcross.org/sg-message-27-sep-2013.htm>
2. Kresie L. Artificial blood: An update on current red cell and platelet substitutes. Proc (Bayl Univ Med Cent). 2001;14(2): 158–161.
3. Bhattacharya N. Placental umbilical cord whole blood transfusion: A safe and genuine blood substitute for patients of the under resourced world at emergency. J Am Coll Surg. 2005;200(4):557-63.

4. Agrawal N. Thesis for: MS (Obstetrics & Gynecology). Transfusion of placental umbilical cord whole blood (Rich In Stem Cells) In Transfusion Dependent Patients And To Assess Its Outcome” September 2016.  
DOI: 10.13140/RG.2.2.33994.98245/1
5. Burlacu A. Umbilical cord blood: Medical waste or important source of stem cells? *Human Genet Embryol S2:005; 2012.*  
DOI: 10.4172/2161-0436.S2-005
6. McCracken S, Layton JE, Shorter SC, Starkey PM, Barlow DH, Mardon HJ. Expression of granulocyte-colony stimulating factor and its receptor is regulated during the development of the human placenta. *J Endocrinol.* 1996;149: 249–58.
7. Hassall O, Maitland K, Fegan G, Thitiri J, Pole L, Mwakesi R et al. The quality of stored umbilical cord and adult-donated whole blood in Mombasa, Kenya *Transfusion.* 2010;50(3):611–16.
8. Liu E, Law HK, Lau YL. Tolerance associated with cord blood transplantation may depend on the state of host dendritic cells. *British Journal of Haematology.* 2004; 126:517-26.
9. Kaladhar K, et al. Possibilities of using cord blood for improving the biocompatibility of implants. In Niranjan Bhattacharya, Phillip Stubblefield. Editors. *Frontiers of Cord Blood Science.* USA Springer. 2009;Chapter: 16:319-330.
10. Niranjan Bhattacharya. Placental umbilical cord whole blood transfusion: A true blood substitute to combat anemia in the background of chronic disease-a study report. (1999-2006). In Niranjan Bhattacharya, Phillip Stubblefield editors. *Frontiers of cord blood Science,* USA Springer. 2009;Chapter: 10:227-57.
11. Halbrecht J. Fresh and stored placental blood. *Lancet.* 1939;2:1263.
12. Hassall O, Bedu-Addo G, Adarkwa M, Danso K, Bates I. Umbilical-cord blood for transfusion in children with severe anaemia in under-resourced countries. *Lancet.* 2003;361(9358):678-79.
13. Bhattacharya N. Placental umbilical cord whole blood transfusion: A safe and genuine blood substitute for patients of the underresourced world at emergency. *J Am Coll Surg.* 2005;200(4):557-63.
14. Eichler H, Schaible T, Richter E, Zieger W, Voller K, Leveringhaus A, et al. Cord blood as a source of autologous RBCs for transfusion to preterm infants. *Transfusion.* 2000;40(9):1111-7.
15. Surbek DV, Glanzmann R, Senn HP, Hoesli I, Holzgreve W. Can cord blood be used for autologous transfusion in preterm neonates? *Eur J Pediatr.* 2000;159(10): 790-1.
16. Brugnara C, Platt OS. The neonatal erythrocyte and its disorders. In: Nathan DG, Orkin SH, Ginsburg D, Look AT, editors. *Hematology of Infancy and Childhood.* 6th edition. Saunders. 2003; 19–55.
17. Matovcik LM, Mentzer WC. The membrane of the human neonatal red cell. *Clinics in Haematology.* 1985;14(1):203–221.
18. Nagel RL. Hemoglobins: Normal and abnormal. In: Nathan DG, Orkin SH, Ginsburg D, Look AT, editors. *Hematology of Infancy and Childhood.* 6th edition. Saunders. 2003;745–789.
19. Ludvigsen BF. Hemoglobin synthesis and function. In: Stiene-Martin EA, Lotspeich-Steininger CA, Koepke JA, editors. *Clinical Hematology: Principles, Procedures, Correlations.* 2nd edition. Lippincott. 1997; 73–86.
20. Oski FA. The unique fetal red cell and its function. E. Mead Johnson Award address. *Pediatrics.* 1973;51(3):494–500.
21. Jain SK. The neonatal erythrocyte and its oxidative susceptibility. *Seminars in Hematology.* 1989;26(4):286–300.
22. Umbilical cord blood transfusions in low-income countries, Elaine Gluckman, Published Online: 13 February 2015.
23. Bhattacharya N, Mukherjee K, Chettri MK, Banerjee T, Mani U, Bhattacharya S. A study report of 174 units of placental umbilical cord whole blood transfusion in 62 patients as a rich source of fetal hemoglobin supply in different indications of blood transfusion. *Clin Exp Obstet Gynecol.* 2001;28(1):47-52.
24. Bhattacharya N. Placental umbilical cord whole blood transfusion to combat anemia in the background of tuberculosis and emaciation and its potential role as an immuno-adjuvant therapy for the under-resourced people of the world. *Clinical and Experimental Obstetrics & Gynecology.* 2005;33(2):99-104.
25. DNJ Lockwood. Treatment of leprosy. *BMJ.* 2004;328:1447.
26. Jyoti Bindal, Nidhi Agrawal, Dharmesh Chandra Sharma. Overview of Referred



- Obstetric Patients and Their Outcome in Tertiary. Care Hospital JMSCR. 2017; 05(05):22485-91.  
Available:<https://dx.doi.org/10.18535/jmscr/v5i5.196>,  
<http://www.stmkolkata.org/rmts/head-of-department%20.html>
27. Hassall OW, Thitiri J, Fegan G, Hamid F, Mwarumba S, Denje D, Wambua K, Mandaliya K, Maitiand K. Safety and efficacy of allogenic umbilical cord red blood cell transfusion for children with severe anemia in a Kenyan hospital: An open-label single-arm trial. *The Lancet*. 2015;2(3):101-7.
28. Hassall OL, Ngina W, Kongo J, Othigo K, Mandaliya K, Maitland I. Bates. The acceptability to women in Mombasa, Kenya, of the donation and transfusion of umbilical cord blood for severe anaemia in young children First published: 07 December; 2007.  
Available:<https://doi.org/10.1111/j.1423-0410.2007.01012.x>
29. Bhattacharya N. A study of placental umbilical cord whole blood transfusion in 72 patients with anemia and emaciation in the background of cancer. *Eur J Gynaecol Oncol*. 2006;27(2):155-61.
30. Noguera NI, Detarsio G, Pérez SM, Bragós IM, Lanza O, Rodríguez JH, et al. Hematologic study of newborn umbilical cord blood. *Medicina (B Aires)*. 1999;59: 446-8.
31. Bhattacharya N. Study of the utility of placental cord blood in meeting the transfusion needs of beta-thalassemic patients. *Regional health forum*. 2008; 12(2):16-27.
32. Bhattacharya N. Spontaneous transient rise of CD34 cells in peripheral blood after 72 hours in patients suffering from advanced malignancy with anemia: effect and prognostic implications of treatment with placental umbilical cord whole blood transfusion. *European Journal of Gynaecological Oncology*. 2005; 27(3):286-90.
33. Ezzedine K, Eleftheriadou V, Whitton M, van Geel, N. "Vitiligo". *Lancet*. 2015; 386(9988):74–84.
34. Openshaw, Amanda (Feb). Understanding Retinitis Pigmentosa (PDF). University of Michigan Kellogg Eye Center; 2008.  
Available:<http://www.med.umich.edu/1libr/Ophthalmology/Retina/RetinitisPigmentosa.pdf>

© 2018 Khatoon et al.; This is an Open Access article distributed under the terms of the Creative Commons Attribution License (<http://creativecommons.org/licenses/by/4.0>), which permits unrestricted use, distribution, and reproduction in any medium, provided the original work is properly cited.

*Peer-review history:*

*The peer review history for this paper can be accessed here:*  
<http://www.sciencedomain.org/review-history/27333>