

Prepubertal testicular tumours: Should testicular-sparing surgery be considered? A single-institution experience and review of the literature

Mohamed H. Zahran, Tamer E. Helmy, Ashraf T. Hafez & Mohamed Dawaba

To cite this article: Mohamed H. Zahran, Tamer E. Helmy, Ashraf T. Hafez & Mohamed Dawaba (2014) Prepubertal testicular tumours: Should testicular-sparing surgery be considered? A single-institution experience and review of the literature, Arab Journal of Urology, 12:2, 130-136, DOI: [10.1016/j.aju.2013.11.003](https://doi.org/10.1016/j.aju.2013.11.003)

To link to this article: <https://doi.org/10.1016/j.aju.2013.11.003>



© 2013 Arab Association of Urology



Published online: 05 Apr 2019.



Submit your article to this journal [↗](#)




Article views: 240



View related articles [↗](#)



View Crossmark data [↗](#)



PEDIATRIC UROLOGY
ORIGINAL ARTICLE

Prepubertal testicular tumours: Should testicular-sparing surgery be considered? A single-institution experience and review of the literature



Mohamed H. Zahran *, Tamer E. Helmy, Ashraf T. Hafez, Mohamed Dawaba

Urology and Nephrology Center, Mansoura University, Mansoura 35516, Egypt

Received 29 June 2013, Received in revised form 6 November 2013, Accepted 13 November 2013
Available online 11 December 2013

KEYWORDS

Paediatric;
Testicular tumours;
Orchidectomy

ABBREVIATIONS

AFP, α -fetoprotein;
HCG, human chorionic gonadotrophin;
RPLND, retroperitoneal lymph node dissection;
US, ultrasonography

Abstract Objectives: To review our 10-year experience with uncommon testicular tumours in children (prepubertal testicular and paratesticular), to review previous reports, and to determine the appropriate management of these rare tumours, specifically the role of testicular-sparing surgery.

Patients and methods: We retrospectively reviewed all cases of testicular tumours managed at our institution between 1999 and 2009. Boys aged < 16 years were included in the study. The patients' characteristics, presentation, the diagnostic tools, tumour markers, mode of treatment, pathological findings and outcome were assessed. We reviewed previous reports that addressed testicular and paratesticular tumours in prepubertal boys, using a Medline/PubMed search.

Results: From 80 patients, 13 boys (median age 8.7 years) presented with testicular tumours (16%) and were included in the study. Two boys presented with precocious puberty and one with gynaecomastia. The level of α -fetoprotein was high in three boys, and the human chorionic gonadotrophin level was elevated in one, and both markers were high in one. Testicular-sparing surgery was performed in three boys. Six of the 13 tumours were malignant and seven were benign. None of the patients developed a recurrence or testicular atrophy after testicular-sparing

* Corresponding author. Tel.: +20 1063338690; fax: +20 50 2263717.

E-mail address: zahranmha@yahoo.com (M.H. Zahran).

Peer review under responsibility of Arab Association of Urology.



Production and hosting by Elsevier

surgery. From the review of previous reports we devised an evidence-based algorithm for managing prepubertal testicular tumours.

Conclusions: Paediatric testicular tumours are rare but they require an inguinal approach for either orchidectomy or testicular-sparing surgery; we recommend the latter option as long as frozen sections are analysed and a safety margin is maintained.

© 2013 Production and hosting by Elsevier B.V. on behalf of Arab Association of Urology.

Introduction

Testicular and paratesticular tumours in children are uncommon, representing 1–2% of all paediatric solid tumours and 3% of all testicular tumours. They occur with an incidence of 0.5–2 per 100,000 children [1]. Historically, yolk-sac tumour has been described as the most common lesion in children, followed by teratoma [2,3]. However, recent studies reported that benign testicular lesions are more common in this age group [4–7]. Traditionally, a radical high inguinal orchidectomy is the treatment of choice, but there are studies reporting the successful management of a benign lesion with a testicular-sparing approach, and with encouraging results in the long-term follow up [4,6,8–11].

We reviewed our 10-year experience with testicular tumours in children and adolescents, and reviewed previous reports to devise an algorithm for managing prepubertal testicular tumours.

Patients and methods

After obtaining internal review board and ethics committee approval, the computerised files of patients who were treated for testicular tumours in our institute between January 1999 and December 2009 were reviewed. Only patients aged ≤ 16 years were included in the study and their files were fully evaluated. The data collected were age at the time of surgery, medical history, surgical history, clinical manifestations, diagnostic tools, tumour marker levels, tumour characteristics, treatment methods, histopathological findings and the outcome. Testicular ultrasonography (US) and tumour marker levels were assessed in all patients. CT of the chest, abdomen and pelvis, and MRI, were used in patients with a suspected malignancy and associated metastasis.

Surgery

All patients were explored via an inguinal incision, with early control of the spermatic cord at the internal inguinal ring. The testis was retrieved through the incision and then the tunica vaginalis was incised. If the tumour had invaded the whole testis, a radical orchidectomy was done. If the tumour was well demarcated it was excised and sent for frozen-section analysis. If confirmed

to be a benign tumour then testicular-sparing surgery was used, but otherwise a radical orchidectomy was done. All tumours excised were sent for histopathological examination after surgery.

Follow-up data were collected from the clinical visit registry. Patients were followed up by a clinical examination and US, and measurement of the serum α -feto-protein (AFP) level. A follow-up CT and chest X-ray were assessed in patients with malignant tumours.

Previous reports in English were identified using a Medline/PubMed search that addressed testicular and/or paratesticular neoplasms in prepubertal males. Using these data and our experience, we devised an evidence-based concise algorithm for managing these uncommon tumours.

Results

Among 80 patients with testicular tumours only 13 were diagnosed in children (median age 8.7 years, range 0.33–16). The tumours affected the right and left testis in seven and six patients, respectively. A painless testicular swelling was the main presenting symptom in 10 patients, with precocious puberty as the presenting symptom in two patients with a Leydig-cell tumour. A patient with a Sertoli-cell tumour presented with gynecomastia. Tumour markers were assessed in all patients and the results are shown in Table 1.

Scrotal US with a Doppler study was used in all patients, and detected all the testicular and paratesticular lesions (sensitivity 100%). CT of the abdomen and pelvis was used in one patient with high levels of both AFP and human chorionic gonadotrophin (HCG), and this detected retroperitoneal lymphadenopathy. MRI was used in two patients with elevated AFP levels, but no extra-testicular lesions were detected.

Table 1 The correlation between tumour marker levels and the pathology of the testicular tumour.

Tumour marker	<i>n</i> Patients	Pathology
Normal	8	
Elevated AFP	3	Yolk sac tumour
Elevated HCG	1	Seminoma
Elevated both	1	Mixed germ cell

US showed well-circumscribed intratesticular lesions with a low blood flow on the Doppler study in two patients. They were treated by testicular-sparing surgery after frozen-section analysis, and the pathology was Leydig-cell tumour and Leydig-cell hyperplasia (Fig. 1). Also, a diffuse enlargement of the right testis with an intratesticular hyperechoic area was detected in a 10-year-old boy. Doppler US showed a normal blood flow. The patient was explored for any possible malignant tumour. On exploration, the right testis was large, with normal intrascrotal structures. The tunica albuginea was opened and an intratesticular small well-defined whitish mass was excised. This was confirmed to be benign macro-orchidism. No patient developed a recurrence or testicular atrophy at the last follow-up (24, 28 and 20 months, respectively).

Ten patients were treated by radical orchidectomy as the testis could not be saved, or the frozen-section analysis confirmed malignancy. Three were yolk-sac tumours, one was a seminoma, one a mixed germ-cell tumour, two were Sertoli-cell tumours, and one each a Leydig-cell tumour, embryonal rhabdomyosarcoma and capillary haemangioma (Table 2).

Six of the 13 patients had malignant tumours; five had stage I tumours with no extra-testicular lesions. Only the patient with a mixed germ-cell tumour had retroperitoneal lymphadenopathy of ≤ 2 cm (stage II). He received adjuvant chemotherapy and was free of disease at the last follow-up.

Patients with benign lesions were not recommended for a close follow-up. Only those patients with endocrine manifestations were referred to a special paediatric endocrinologist. Patients with malignant pathology were followed up at the outpatient clinic, and all were alive with no recurrence or metastasis at a median follow-up of 22.5 months. The levels of tumour markers returned to normal values after surgery in all cases except in the patient with a mixed germ-cell tumour, where marker levels returned to normal values after adjuvant chemotherapy.

Discussion

These rare prepubertal testicular and paratesticular tumours are distinct from those in adults. The incidence of prepubertal testicular tumours has not increased significantly over the last three decades, but the incidence has increased in postpubertal populations [2]. Testicular tumours have a bimodal age distribution, occurring in young adults, and with a distinct peak in the first 3 years of life, but with a much lower incidence than in adults [12].

The commonest type of prepubertal testicular tumour is the malignant yolk-sac tumour, followed by teratoma [2]. Furthermore, the 30-year data from one centre in Turkey showed that yolk-sac tumour is the most common type [3]. Analysis of data from four paediatric centres in the USA showed a much higher proportion of

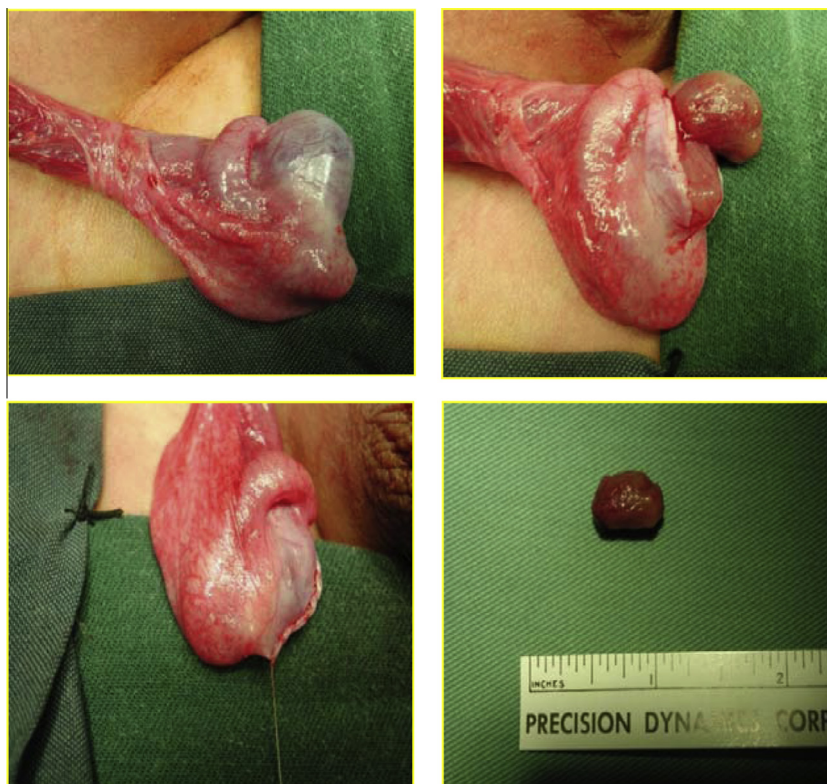


Figure 1 Intraoperative views from an 11-year-old boy with a right Leydig cell tumour.

Table 2 The clinical characteristics and management of the various prepubertal testicular tumours.

Pathology	<i>n</i>	Median age (years)	Side	Treatment	Median follow-up (months)
<i>Germ cell tumours</i>					
Benign	0				
Malignant	5				
Yolk sac	3	7.5	Left (2), right (1)	RO	12
Seminoma	1	13	Right	RO	16
Mixed germ-cell tumour	1	8	Left	RO + chemotherapy	15
<i>Sex-cord stromal tumour</i>					
Benign	4				
Leydig cell	2	11	Right (1), left (1)	RO (1), testicular-sparing (1)	24
Sertoli cell	2	3.5	Left	RO	–
Malignant	0				
<i>Paratesticular tumours</i>					
Benign	1				
Haemangioma	1	16	Right	RO	
Malignant	1				
Embryonal Rhabdomyosarcoma	1	10	Right	RO	36
<i>Others</i>					
Macro-orchidism	1	10	Right	Testicular-sparing	20
Leydig cell hyperplasia	1	3	Right	Testicular-sparing	28

RO, radical orchidectomy.

teratoma, in half of cases [5]. Similar results were reported from several single institutions [4,6,7]. Regardless of the actual distribution, yolk-sac tumours and teratomas are the most common prepubertal testicular tumours, but most postpubertal testicular tumours are malignant germ-cell tumours (seminomas). In the present series malignant tumours comprised about half and no cases of teratoma were diagnosed.

A painless scrotal swelling is the main symptom in 85–90% of cases, followed by an incidental diagnosis after trauma, or with hydrocele or hernia [4]. In the present study three-quarters of patients presented with a painless mass. Consistent with other reports, scrotal US with a Doppler study distinguished intratesticular masses from extratesticular masses and other scrotal pathologies, with complete sensitivity [12,13].

A metastatic evaluation using CT and/or MRI of the abdomen, pelvis and chest is used only if there is a high risk of metastasis, to determine the preoperative staging and plan for therapy. It is indicated in two conditions: First, in a patient aged >6 months with high AFP levels, as this suggests a yolk-sac tumour with a high risk of metastasis to lung or retroperitoneum. The second condition is a confirmed malignant histological diagnosis [14]. In the present series the metastatic evaluation was preoperative in three patients with elevated tumour marker levels, and retroperitoneal lymphadenopathy was detected in one. CT was used after surgery in patients with a confirmed embryonal rhabdomyosarcoma, and no evidence of metastasis was detected.

The tumour markers HCG and AFP are important for the diagnosis of postpubertal testicular tumours. However, HCG has no clinical significance in the prepubertal group, as choriocarcinoma and embryonal carcinoma are rare in this group [15]. AFP is important in the diagnosis, staging and follow-up of prepubertal testicular tumours, as yolk-sac tumour, which is the commonest, is associated with high AFP levels in >90% of cases. Normally the AFP level is high in neonates and infants, and returns to normal levels after 6–8 months of age. In yolk-sac tumours AFP increases to a high level and does not return to normal. Teratoma can lead to an increase in AFP levels, but not to high levels (<100 ng/mL in infants aged >6 months). This finding can affect the decision as to whether a child will have testicular-preserving surgery or a radical orchidectomy [16]. In the present series AFP levels increased in all cases with yolk-sac tumours and in the patient with a mixed germ-cell tumour.

Teratoma (mature and immature) and epidermoid cysts are the commonest prepubertal testicular benign germ-cell tumours [17]. Being benign and not tending to recur, and as metastasis is rare, testicular-sparing surgery has become the standard of care and a detailed follow-up is not necessary [6,8–11].

Yolk-sac tumour is the commonest tumour in the prepubertal age group. It metastasises by haematogenous spread and the incidence of retroperitoneal metastasis is only 4–6%. In contrast to postpubertal cases, radical orchidectomy is the standard of care for stage I

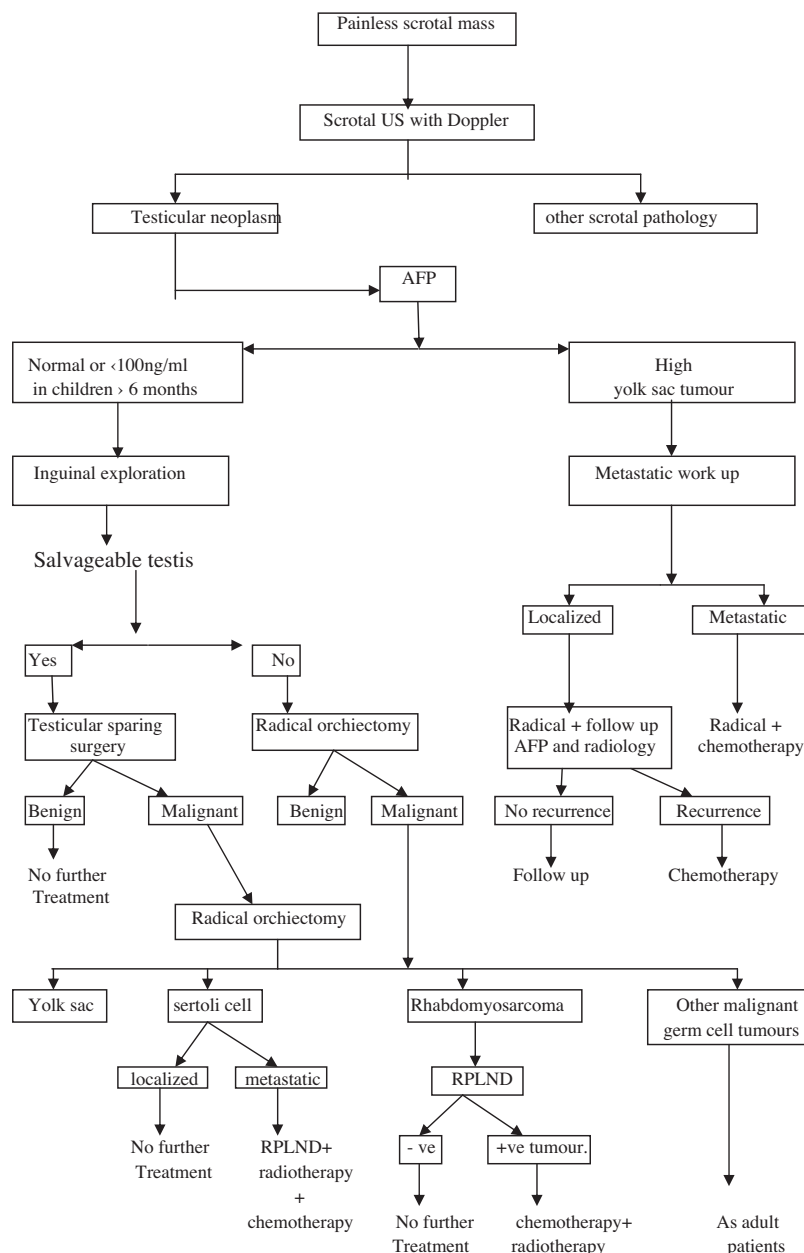


Figure 2 The algorithm for managing prepubertal testicular tumours.

disease, with follow-up by AFP levels and CT. Any recurrence responds well to platinum-based chemotherapy [18]. Radical orchidectomy and chemotherapy is the standard management of patients with stage II and metastatic disease. A retroperitoneal lymph-node dissection (RPLND) is therefore reserved for patients in whom there is persistent retroperitoneal lymphadenopathy or a persistently high AFP level [18]. The three patients with yolk-sac tumours in the present series had stage I disease and were treated by radical orchidectomy, with a return of AFP to normal levels after surgery, and with no recurrence or metastasis at a median follow-up of 12 months.

Sex-cord stromal tumours are rare at a prepubertal age. Juvenile granulosa-cell tumours and Leydig-cell tumours are always benign, and most Sertoli-cell tumours are benign, although rare cases can show malignant behaviour. In the present series there were two patients with Leydig-cell tumours and a third with Leydig-cell hyperplasia. Two patients were treated by testicular-sparing surgery. Similar results were reported by Taskinen et al. [7] and Wang et al. [15], with no recurrence or testicular atrophy.

Two patients with Sertoli-cell tumour were treated by a high inguinal orchidectomy and no further follow-up was required, as both had a confirmed benign

histopathology. This is consistent with the reported predominance of benign Sertoli-cell tumours in children [18,19]. Malignant cases were reported in older children and adequate staging is required. If any metastasis is present, a radical orchidectomy followed by RPLND, chemotherapy and radiotherapy is the best treatment [16,18].

Paratesticular tumours are rare in prepubertal patients. Testicular-sparing surgery is the standard treatment for benign tumours [15]. In the patient with a haemangioma, this was suspected during surgery and testicular-sparing surgery was deemed unsuitable. The diagnosis was confirmed by final histopathology and no further follow-up was necessary.

Rhabdomyosarcoma is the most common spermatic-cord sarcoma, and represents 5% of all testicular and paratesticular tumours. The distribution is bimodal, with peaks at 3–4 months and at 16 years [18]. It is an aggressive tumour that infiltrates locally and metastasises via the lymphatic system and bloodstream. However, paratesticular rhabdomyosarcoma has a better prognosis than at other sites, with a 95% 3-year survival rate. Being a malignant tumour, radical orchidectomy followed by RPLND and chemotherapy is the recommended treatment, except in boys aged < 10 years with a localised tumour [20]. We reported a 10-year-old boy with an embryonal rhabdomyosarcoma, with no evidence of metastasis and who remained disease-free at a follow-up of 36 months after radical orchidectomy only. This was previously reported by Ciftci et al. [21], and Wang et al. [15] reported the same outcome with radical orchidectomy and adjuvant chemotherapy.

There are several limitations to the present study. The inherent criterion of a retrospective analysis is the main drawback. In addition, there were few patients, but prepubertal testicular tumours are rare, affecting only a few of the tens of millions of susceptible boys. Our results are in parallel to those of the major cancer registry data, where yolk-sac tumour is the commonest, and the results differ from those in other recent single-centre studies. Our review of previous reports helped us to design an algorithm for managing prepubertal testicular tumour in an easily applicable way (Fig. 2).

In conclusion, prepubertal testicular tumours are uncommon, with benign tumours more common in this age group, and testicular-sparing surgery is therefore a safe and effective treatment that should be tried in all cases. Yolk-sac tumour is the commonest prepubertal malignant testicular tumour and radical orchidectomy is sufficient for cancer control in patients with localised disease. Although teratoma was not detected in our series, it is reported to be the second most common type and should be considered.

Conflict of interest

The authors have no conflict of interest to declare.

Source of funding

None.

References

- [1] Kay R. Prepubertal testicular tumor registry. *J Urol* 1993;**150**: 671–4.
- [2] Ross JH, Rybicki L, Kay R. Clinical behavior and a contemporary management algorithm for prepubertal testis tumors: a summary of the prepubertal testis tumor registry. *J Urol* 2002;**168**:1675–8.
- [3] Sugita Y, Clarnette TD, Cooke- Yarborough C, Chow CW, Waters K, Hutson JM. Testicular and paratesticular tumours in children: 30 years' experience. *Aust NZ J Surg* 1999;**69**: 505–8.
- [4] Metcalfe PD, Farivar-Mohseni H, Farhat W, McLorie G, Khoury A, Bägli DJ. Pediatric testicular tumors. Contemporary incidence and efficacy of testicular preserving surgery. *J Urol* 2003;**170**:2412–5.
- [5] Pohl HG, Shukla AR, Metcalf PD, Cilento BG, Retik AB, Bägli DJ, et al. Prepubertal testis tumors. Actual prevalence rate of histological types. *J Urol* 2004;**172**:2370–2.
- [6] Alanee S, Shukla A. Paediatric testicular cancer. An updated review of incidence and conditional survival from the surveillance, epidemiology and end results database. *BJU Int* 2009;**104**: 1280–3.
- [7] Taskinen S, Fagerholm R, Aronniemi J, Rintala R, Taskinen M. Testicular tumors in children and adolescents. *J Pediatr Urol* 2008;**4**:134–7.
- [8] Rushton HG, Belman AB, Sesterhenn I, Patterson K, Mostofi FK. Testicular sparing surgery for prepubertal teratoma of the testis: a clinical and pathological study. *J Urol* 1990;**144**:726–30.
- [9] Oottamasathien S, Thomas JC, Adams MC, DeMarco RT, Brock JC, Pope JC, et al. Testicular tumors in children: a single-institutional experience. *BJU Int* 2007;**99**:1123–6.
- [10] Hisamatsu E, Takagi S, Nakagawa Y, Sugita Y, Yoshino K, Ueoka K, Tanikaze S. Prepubertal testicular tumors: a 20-years experience with 40 cases. *Int J Urol* 2010;**17**:956–9.
- [11] Bujons A, Sfulcini JC, Pascual M, Feu OA, Garat JM, Villavicencio H. Prepubertal testicular tumours and efficacy of testicular preserving surgery. *BJU Int* 2011;**107**:1812–6.
- [12] Schneider DT, Calaminus G, Koch S, Teske C, Schmidt P, Haas RJ, et al. Epidemiologic analysis of 1442 children and adolescents registered in the German germ cell tumor protocols. *Pediatr Blood Cancer* 2004;**42**:169–75.
- [13] Treiyer A, Blanc G, Stark E, Haben B, Treiyer E, Steffens J. Prepubertal testicular tumors: frequently overlooked. *J Pediatr Urol* 2007;**3**:480–3.
- [14] Valla JS. for the Group D'Etude en Urologie. Pédiatrique. Testis-sparing surgery for benign testicular tumors in children. *J Urol* 2001;**165**:2280–3.
- [15] Wang X, Xu S, Tang D, Li M, Wu D, Huang Y. Prepubertal testicular and paratesticular tumors in China: a single-center experience over a 10-years period. *J Pediatr Surg* 2012;**47**: 1576–80.
- [16] Ross JH, Kay R. Prepubertal testis tumors. *Rev Urol* 2004;**6**:11–8.
- [17] Khemakhem R, Ahmed YB, Jlidi S, Nouria F, Fdhila F, Charieg A, et al. Testicular tumours in prepubertal children: about eight cases. *Afr J Paediatr Surg* 2013;**10**:176–9.

- [18] Rogers PC, Olson TA, Cullen JW, Billmire DF, Marina N, Rescorla F, et al. Treatment of children and adolescents with stage II testicular and stages I and II ovarian malignant germ cell tumors: a pediatric intergroup study – pediatric oncology group 9048 and children’s cancer group 8891. *J Clin Oncol* 2004;**22**:3563–9.
- [19] Burgu B, Aydogdu O, Telli O, Kankaya D, Soygur T, Baltaci S, et al. An unusual cause of infantile gynecomastia: Sertoli cell tumor. *J Pediatr Hematol Oncol* 2011;**33**:238–40.
- [20] Raney RB, Anderson JR, Barr FG, Donaldson SS, Pappo AS, Qualman SJ, et al. Rhabdomyosarcoma and undifferentiated sarcoma in the first two decades of life: a selective review of intergroup rhabdomyosarcoma study group experience and rationale for intergroup rhabdomyosarcoma study V. *J Pediatr Hematol Oncol* 2001;**23**:215–20.
- [21] Ciftci AO, Bingöl-Kologlu M, Senocak ME, Tanyel FC, Büyükpamukçu M, Büyükpamukçu N. Testicular tumors in children. *J Pediatr Surg* 2001;**36**:1796–801.