

# Kounis Syndrome: Is it a Herald or Just a Mimicker of Acute Coronary Syndrome?

TAGADUR NATARAJU KAMALESH<sup>1</sup>, SOMASHEKAR NISHANTH<sup>2</sup>,  
MANDYA DODDACHARY AKANKSH<sup>3</sup>, KARTHIK NAVEEN<sup>4</sup>



## ABSTRACT

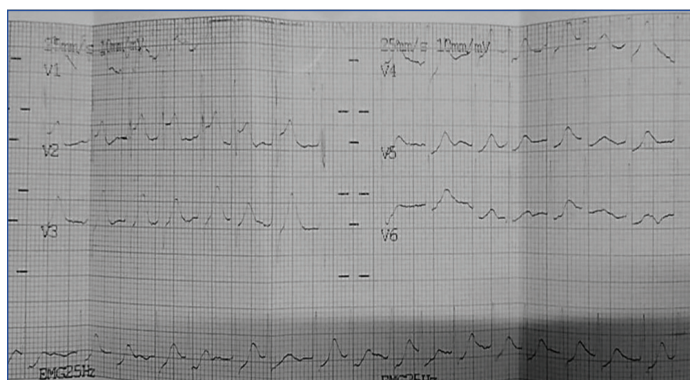
Coronary vasospasm of allergic aetiology is a heavily underdiagnosed condition. Very few instances of this phenomenon are reported. This is a case of a 55-year-old male, with an unusual presentation, where a bee sting triggered an allergic inflammatory reaction, leading to release of inflammatory cytokines resulting in coronary vasospasm. This is evidenced by ST segment elevations at the time of presentation. This ST segment changes resolves on taking antihistaminic and corticosteroid medication. The resolution of symptoms and Electrocardiogram (ECG) findings after treatment with antihistaminic and corticosteroid proved that, the symptoms were primarily caused by an allergic reaction. The present case report explained that, coronary vasospasm can occur due to hypersensitivity reactions and can be treated promptly with antihistaminic and immunosuppressive (hydrocortisone) drugs.

**Keywords:** Allergic reaction, Coronary vasospasm, Cytokines

## CASE REPORT

A 55-year-old male, presented with the chief complain of chest pain, diaphoresis and headache since one hour, after he got stung by honey bees. There was no history of urticaria, angioedema, breathing difficulties or nausea. The patient did not show any angina like symptoms in the past. The patient was a known case of type II Diabetes Mellitus (DM), Hypertension (HTN), and was on regular medication. The patient was a non smoker, non alcoholic and had no family history of coronary artery disease. At presentation, the patient was afebrile with multiple bee sting marks along with the oedema and erythema. The patient's vital parameters were recorded as, the heart rate was 126 beats per minute, blood pressure recorded 140/90 mmHg and oxygen saturation was 97% on room air. Examination of the central nervous system, cardiovascular system, respiratory system and abdomen revealed no abnormalities.

The ECG showed ST elevation of 3 mm in leads V1 and V2 with sinus tachycardia [Table/Fig-1]. No abnormalities in serum electrolytes, renal function and liver function tests were noted. Lipid profile and blood sugars were within the normal range.

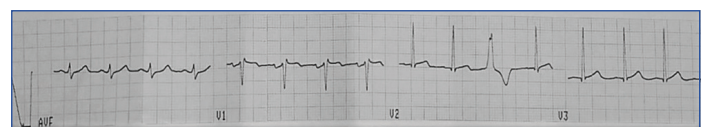


**[Table/Fig-1]:** 12 lead ECG at admission: sinus tachycardia with ST elevation in leads V1 and V2 and ST depression in lead V2.

The patient was given Intravenous (i.v.) antihistaminic chlorpheniramine, 200 mg intravenous hydrocortisone and intravenous acetaminophen for two days. Tachycardia was resolved and a repeat ECG after the above intervention, showed complete resolution of ST elevation in lead V2 and partial resolution in lead V1. There was new onset benign ventricular premature complex in lead V2 [Table/Fig-2]. The bedside ECG showed, good left ventricular

function and no Regional Wall Motion Abnormalities (RWMA). Cardiac biomarker troponin was found to be normal with slightly elevated Creatine Kinase-myocardial Band (CK-MB) levels.

Since, there was a resolution of ST elevation, after the treatment of allergic reaction [Table/Fig-2], the possibility of histamine-induced coronary vasospasm from honey bee stings was considered. The patient was referred to a cardiologist, for the evaluation of coronary circulation. It was inferred from coronary angiography, that the patient had left anterior descending coronary artery with 60% occlusion, which did not require percutaneous intervention. The patient was started on Aspirin-Clopidogrel Dual Anti-Platelet Therapy (DAPT) and a statin for coronary artery disease. The patient was asymptomatic after the intervention. He was discharged with a diagnosis of Kounis Syndrome (KS) after three days of admission. The patient was followed-up after two weeks with no complaints, asymptomatic and was able to carry out his routine activities.



**[Table/Fig-2]:** 12 lead ECG after anti-allergy treatment: resolution of ST elevation in lead V1 (partial resolution) and lead V2 (complete resolution). New onset benign Premature Ventricular Contraction (PVC) in lead V2.

## DISCUSSION

The KS is a hypersensitivity coronary disorder, associated with allergic or anaphylactic reactions [1]. It is also described as "allergic angina syndrome" which is a coronary spasm, that progresses to allergic acute Myocardial Infarction (MI) [2]. The most commonly affected age group is 40-70 year-old, although, it can affect people of any age group [3]. Risk factors include HTN, DM, prior allergy, smoking and dyslipidaemia. The pathophysiology of KS involves the release of inflammatory mediators by activated mast cells which are abundant in cardiac tissues [4]. These mediators cause vasospasm of coronary arteries and/or rupture or erosion of atheromatous plaque [5]. This is considered as a under diagnosed syndrome, there are a few reports, describing its occurrence and management. The above mentioned case is a classical case of type 1 KS, which is the most common type, according to previous literature and is caused by coronary vasospasm due to an allergic reaction to an underlying coronary artery disease leading to transient myocardial ischaemia

and consequent ST elevation on ECG. Kounis NG and Zavras GM reported the first case of KS in 1991, which is a case of type 1 KS [2]. Even before this, American Heart Journal in 1950, published the first case of allergic angina due to prolonged use of penicillin [6]. Forman MB et al., describe a case of severe allergic vasospastic angina and sudden death, where, the autopsy showed mast cell infiltration at the site of coronary artery spasm [7]. KS includes many disorders in which mast cell activation is associated with acute coronary syndrome [8,9]. These include reactions to multiple medications (anticancer drugs, antibiotics, Non-steroidal Anti-inflammatory Drugs (NSAIDs), bee stings and intravenous contrast. There is mast cell degranulation due to allergic reaction and subsequent release of multiple chemical mediators like histamine, a variety of cytokines, neutral proteases, arachidonic acid products and platelet activating factor [10]. These mediators lead to coronary vasospasm and plaque rupture resulting in acute coronary syndrome. There is also a release of tryptase which in turn activates interstitial collagenase, gelatinase and stromelysin which erode the atheromatous plaques leading to plaque rupture and initiation of inflammatory cascade leading to acute thrombus formation [11].

Three variants of KS are reported. The most common among them is the type 1 variant, in which there is coronary spasm induced by inflammatory mediators with or without an increase of cardiac biomarkers in the serum. Type 2 variant manifests as acute MI due to rupture or erosion of plaque along with coronary arterial spasm. In the type 3 variant, there is thrombosis of coronary artery stent [12]. ST elevation, may lead to therapeutic dilemma as there can be benign ST elevation due to allergic reaction and at times this coronary vasospasm can lead to turbulent coronary blood flow and consequent plaque rupture leading to acute coronary syndrome. Hence, all patients with suspected KS should undergo subsequent coronary angiography after initial treatment of allergic reaction following bee stings. There is no standard protocol regarding the diagnosis and treatment of KS as these cases are rare and under-reported. However, most of the cases of KS managed according to literature, worldwide followed the protocol of aborting the anaphylactic reaction by using corticosteroids, antihistaminics, and adrenaline followed by stabilising the coronary vasculature with interventions or medications [13]. However, the literature on the occurrence of this due to other forms of allergy is sparse.

Commonly, patients are hypotensive at the time of admission. But in the index case, the blood pressure was normal, same as the case reported by Rao ST et al., [14]. There were no allergic skin manifestations such as urticaria, angioedema and evidence of bronchospasm, which were much more common in cases described in previous literature. ECG revealed elevation of ST segment in anterior leads V1 and V2 compatible with acute anterior wall MI. While, coronary angiography showed 60% occlusion of left anterior descending artery similar to a case described by Karimlu M et al., [15]. The patient was treated with i.v. antihistaminic

(chlorpheniramine), i.v. corticosteroid (hydrocortisone) to abort the anaphylactic reaction similar to the management of the majority of cases previously described in the literature, following which the ST segment changes resolved promptly suggesting an allergic aetiology for the MI occurred. Antiplatelets (aspirin and clopidogrel) and statin were used to treat acute coronary event with no other intervention needed. The prognosis is usually poor, due to life threatening anaphylactic shock with the involvement of the cardiovascular system. However, in the present case, as the allergic reaction and coronary event were promptly recognised and reversed, symptoms subsided with a shorter hospital stay, the prognosis is good.

## CONCLUSION(S)

A rare case of KS characterised by ST elevation, secondary to coronary vasospasm, following honeybee sting is described here. Any form of ST elevation, following honeybee stings or scorpion sting should be subjected for evaluation of coronary circulation in spite of the resolution of ST elevation, with the treatment of allergy.

## REFERENCES

- [1] Kounis NG. Kounis syndrome: an update on epidemiology, pathogenesis, diagnosis and therapeutic management. *Clin Chem Lab Med.* 2016;54(10):1545-59.
- [2] Kounis NG, Zavras GM. Histamine-induced coronary artery spasm: the concept of allergic angina. *Br J Clin Pract.* 1991;45:121-28.
- [3] Abdelghany M, Subedi R, Shah S, Kozman H. Kounis syndrome: A review article on epidemiology, diagnostic findings, management and complications of allergic acute coronary syndrome. *Int J Cardiol.* 2017;232:01-04.
- [4] Brown SG. Cardiovascular aspects of anaphylaxis: implications for treatment and diagnosis. *Curr Opin Allergy Clin Immunol.* 2005;5(4):359-64.
- [5] Gázquez V, Dalmau G, Gaig P, Gómez C, Navarro S, Mercé J. Kounis syndrome: report of 5 cases. *J Investig Allergol Clin Immunol.* 2010;20(2):162-65.
- [6] Pfister CW, Plice SG. Acute myocardial infarction during a prolonged allergic reaction to penicillin. *Am Heart J.* 1950;40:945-47.
- [7] Forman MB, Oates JA, Robertson D, Robertson RM, Roberts LJ, 2nd, Virmani R. Increased adventitial mast cells in a patient with coronary spasm. *N Engl J Med.* 1985;313:1138-41.
- [8] Lopez PR, Peiris AN. Kounis syndrome. *South Med J.* 2010;103:1148-55.
- [9] Waller BF. Non atherosclerotic coronary heart disease. In: Fuster V, Wane Alexander A, O'Rourke RA. eds. *Hurst's The Heart*, 13th edn. New York: McGraw-Hill; 2010.
- [10] Kounis NG. Kounis syndrome (allergic angina and allergic myocardial infarction): a natural paradigm? *Int J Cardiol.* 2006;110:07-14.
- [11] Mytas DZ, Stougiannos PN, Zairis MN, Tsiaousis GZ, Foussas SG, Hahalis GN, et al. Acute anterior myocardial infarction after multiple bee stings. A case of Kounis syndrome. *Int J Cardiol.* 2009;134:e129-31.
- [12] Kounis NG, Koniari I, Velissaris D, Tzani G, Hahalis G. Kounis syndrome-not a single-organ arterial disorder but a multisystem and multidisciplinary disease. *Balkan Med J.* 2019;36:212-21.
- [13] Doğan V, Mert GÖ, Biteker FS, Mert KU, Biteker M. Treatment of Kounis syndrome. *Int J Cardiol.* 2015;181:133-34.
- [14] Rao ST, Basappa H, Raveesh H, Hegde S, Manjunath CN. Acute Coronary syndrome following honey bee sting: A series of 6 cases of "kounis syndrome" with literature review. *J Indian Coll Cardiol.* 2021;11:98-103.
- [15] Karimlu M, Alavi-Moghaddam A, Rafizadeh O, Azizpour A, Khaheshi I. Acute extensive anterior ST elevation myocardial infarction following bee sting: a rare report of Kounis syndrome in LAD territory. *Cardiovascular Diagnosis and Therapy.* 2016;6(5):466-68.

### PARTICULARS OF CONTRIBUTORS:

1. Associate Professor, Department of Internal Medicine, SS Institute of Medical Sciences and Research Centre, Davanagere, Karnataka, India.
2. Intern, Department of Internal Medicine, SS Institute of Medical Sciences and Research Centre, Davanagere, Karnataka, India.
3. Intern, Department of Internal Medicine, SS Institute of Medical Sciences and Research Centre, Davanagere, Karnataka, India.
4. Junior Resident, Department of Internal Medicine, K.V.G Medical College and Hospital, Dakshina, Kannada, Karnataka, India.

### NAME, ADDRESS, E-MAIL ID OF THE CORRESPONDING AUTHOR:

Tagadur Nataraju Kamalesh,  
SS High Tech Hospital, NH-4 Bypass Road, Davanagere-577005, Karnataka, India.  
E-mail: tnkamalesh@gmail.com

### AUTHOR DECLARATION:

- Financial or Other Competing Interests: None
- Was informed consent obtained from the subjects involved in the study? Yes
- For any images presented appropriate consent has been obtained from the subjects. Yes

### PLAGIARISM CHECKING METHODS: [Jain H et al.]

- Plagiarism X-checker: Oct 31, 2022
- Manual Googling: Jan 04, 2023
- iThenticate Software: Jan 20, 2023 (11%)

### ETYMOLOGY: Author Origin

EMENDATIONS: 5

Date of Submission: **Oct 29, 2022**  
Date of Peer Review: **Dec 21, 2022**  
Date of Acceptance: **Jan 21, 2023**  
Date of Publishing: **Jun 01, 2023**