

Pantaloon Hernia in a Woman: A Straddling Rarity

Rajat Choudhari^{1*}, V. Pon Rachel¹ and Pranay Gaikwad¹

¹Department of Surgery, Christian Medical College and Hospital, Vellore–632004, Tamil Nadu, India.

Authors' contributions

This work was carried out in collaboration between all authors. Author RC performed the literature review and wrote the first draft of the manuscript. Author VPR performed the literature review, case presentation and consent. Author PG managed the case presentation, literature review and manuscript writing. All authors read and approved the final manuscript.

Article Information

DOI: 10.9734/AJCRS/2018/44427

Editor(s):

(1) Dr. Luis Ricardo Martinhao Souto, Assistant Professor, Surgery Division, School of Medical Sciences, Universidade de Marília (UNIMAR), Sao Paulo State, Brazil.

Reviewers:

- (1) Einar Arnbjörnsson, Lund University, Sweden.
(2) Ngowe Ngowe Marcelin, University of Buea, Cameroon.
(3) Hakan Kulacoglu, Turkey.

Complete Peer review History: <http://www.sciencedomain.org/review-history/26808>

Case Report

Received 04 August 2018
Accepted 13 October 2018
Published 24 October 2018

ABSTRACT

Introduction: Inguinal hernias are the commonest hernias in males and females. However, direct hernias are rare in females. Pantaloon hernia (combined direct –indirect hernia) is even rarer and there has been a single study reporting the incidence of pantaloon hernia to be 1.6%. Here, we report a 56-year-old female patient who was clinically diagnosed to have right sided uncomplicated, indirect inguinal hernia but intra-operatively found to have a pantaloon hernia.

Case Presentation: The patient was a 56-year-old female, diabetic and hypertensive with chronic kidney disease with a right inguinal swelling and a clinical diagnosis of an indirect inguinal hernia, planned for mesh hernioplasty. Intra-operatively, she was found to have 2 hernial sacs on either side of the inferior epigastric artery. The posterior wall was defective along with the entire length of the inguinal canal. She underwent resection of the round ligament with invagination of direct sac by suturing of transversalis fascia and herniotomy of the indirect sac. The posterior wall was reinforced with Lichtenstein tension free polypropylene mesh repair.

Discussion: The rarity of direct and hence, pantaloon hernia in women can be explained by the anatomical differences in the inguinal canal and abdominal wall between males and females. Pantaloon hernia is treated as any other inguinal hernia and options of open and laparoscopic repairs including TAPP and TEP are available depending on the surgical expertise and cost factors.

Conclusion: Direct inguinal hernias do occur in women albeit very rarely while pantaloons hernias are extremely rare and when present, may be associated with the testicular feminisation syndrome in young children. The present case is reported with the purpose of documenting the extreme rarity of pantaloons hernia in adult women in the existing scientific literature.

Keywords: Pantaloons hernia; inguinal hernia; complete androgen insensitivity syndrome.

1. INTRODUCTION

Inguinal hernias are the most common type of a primary hernia in both males and females. Even in women, the most common type of the hernias is either indirect inguinal or femoral. Whereas indirect hernias account for 70–80%, femoral hernias constitute about 20% of all hernias. Groin hernias are one of the common causes of chronic pelvic pain in women and can cause a significant disability [1]. A lot of indirect hernias in females can be occult due to a location in the canal of Nuck. Those that become symptomatic usually require prompt treatment [2,3].

About 8% of the total groin hernia surgeries are done in women. Direct hernias per se, are very rare in females due to anatomical differences as compared to males. The incidence of a direct hernia in women has been reported to range from 3% to 14% [3,4]. Pantaloons a hernia (combined direct-indirect hernia) is a very rare variety of an inguinal hernia where both the direct and indirect hernias exist on either side of the inferior epigastric artery.

The most commonly used techniques are the Lichtenstein mesh repair and laparoscopic repair. Here we report a case of a Pantaloons hernia in a female that was managed with the Lichtenstein

tension-free mesh hernioplasty. It is the first case report of its kind in English literature to the best of our knowledge.

2. CASE PRESENTATION

A 56-year-old female, diabetic and hypertensive with chronic kidney disease, presented with a progressively increasing swelling in the right groin associated with dragging type of pain, and difficulty in initiating micturition for six months.

On examination, there was a 5 x 5 cm² swelling in the right inguinal region, located above and medial to the pubic tubercle with an expansile cough impulse with a smooth surface and doughy consistency. The swelling was completely reducible and failed to appear with the deep inguinal ring occlusion test.

With the clinical impression of an incomplete, uncomplicated, completely reducible right indirect inguinal hernia, she was planned for mesh hernioplasty.

Intra-operative findings revealed the presence of both direct and indirect herniae as evidenced by two distinct peritoneal sacs on either side of the inferior epigastric artery (Figs. 1, 2.) The posterior wall was defective along with the entire length of the inguinal canal.

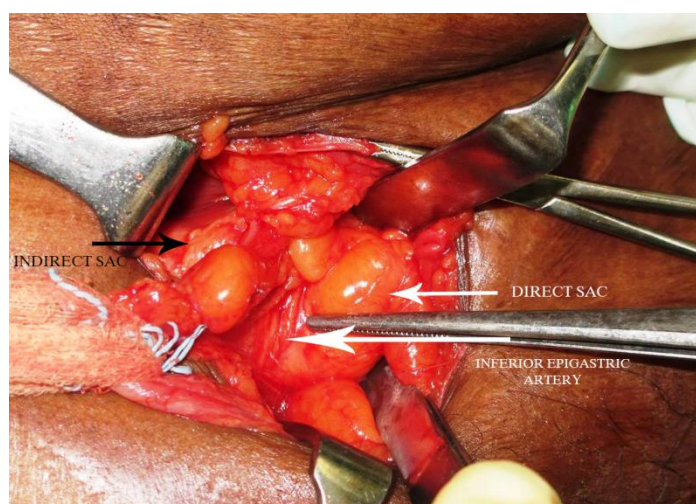


Fig. 1. Pantaloons hernia with 2 sacs on either side of inferior epigastric artery

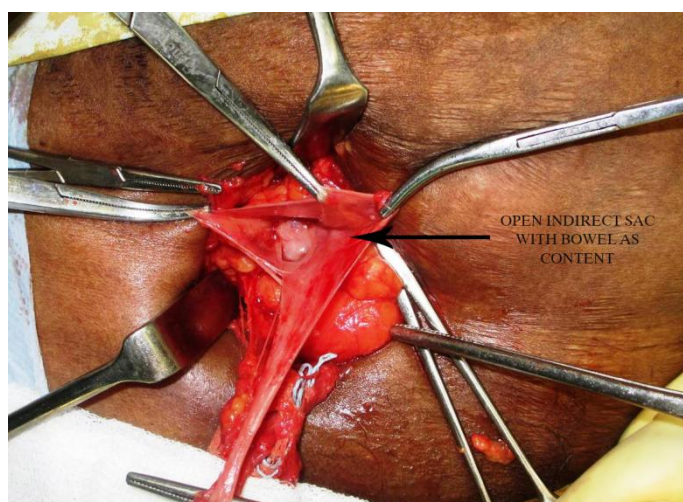


Fig. 2. Opened indirect sac with bowel as content

2.1 Treatment

The patient was planned for surgical treatment with Lichtenstein technique. Open repair was chosen above laparoscopic in view of cost constraints. Inguinal incision was made and dissection was commenced till the hernial sacs were identified. On identification and discovery of a pantaloon hernia, it was decided to perform herniotomy of the indirect sac followed by hernioplasty to cover both the defects. She underwent resection of the round ligament with invagination of the direct sac by suturing the transversalis fascia and herniotomy of the indirect sac. The posterior wall of the inguinal canal was then reinforced by placing a polypropylene mesh with Lichtenstein technique.

2.2 Outcome and Follow Up

The immediate post-operative period was uneventful and she was discharged in a stable condition. In view of her old age and normal sexual development, testicular feminisation syndrome was not considered a possibility. The patient has done well post-operatively with no clinical evidence of recurrence at 6 months of follow up.

3. DISCUSSION

The inguinal canal, in males, is formed due to the descent of the testes from the abdomen into the scrotum by the gubernaculum which attaches the inferior pole of the testes to the scrotum. In females the gubernaculum attaches the ovaries to the labia majorum. However, due to

attachment of the ovaries to the uterus by the ovarian ligament, they do not descend into the labia but remain in the pelvis. The gubernaculum, however, descends into the labia through the inguinal canal. The persistent canal in females is called the canal of Nuck. The gubernaculum later gives rise to the round ligament of the uterus which joins the uterus to the labia majorum through the inguinal canal [5].

Initially it was believed that direct hernias were an impossibility in women. However, it has been shown that though uncommon, they do occur in women. The incidence of direct and pantaloon hernia in women being 3.5% and 1.6% as compared to 21% and 5% in men [2]. This relative difference in the incidence is attributed to the anatomical differences in the abdominal wall and the canal between men and women. Due to the need to bear the stress of pregnancy and childbirth, the transverses abdominis muscle is relatively stronger in women leading to less chances of direct hernia [2]. Anatomical studies have shown that the posterior wall of the inguinal canal in females is stronger than males [6]. The distance between the pubic tubercle and the deep inguinal ring is larger and the rectus sheath is wider in females than the males. The rectus muscle is significantly wider and the internal ring itself is narrower in women due to the thinner and fewer contents - primarily the round ligament [7]. Also, the aponeurotic fibres of the transverse abdominis are deficient medially in men causing a defective shutter mechanism resulting in increased incidence of direct hernias [2]. The difference also has been attributed to a defective collagen synthesis due to exogenous causes (smoking and alcohol consumption) and

endogenous causes like androgens [2]. Thus, several factors have been suggested to cause the differences in the propensity of hernia formation between men and women [8].

In women, the most common content in a direct hernia is the ovary but may include the uterus and the urinary bladder. This has been attributed to the altered anatomy and localisation of the female gubernaculum due to androgen insensitivity. This theory has been supported by the fact that approximately 1.6% of the children presenting with an inguinal hernia and having apparent female genitalia prove to be of male nuclear sex with intra-abdominal testes but female anatomy and endocrine function-complete androgen insensitivity syndrome previously called the testicular feminization syndrome [8].

Pantaloon hernias are very rare in women. Only a single study has reported the incidence of pantaloon hernia to be 1.8% in females and 5.6% in males from a single centre [4]. Review of surgical literature showed no other cases or incidences reported. It is believed that a large indirect hernia may cause dilatation of the deep ring leading to weakening of the posterior wall which may cause bulging of the hernial sac on both sides of the inferior epigastric vessels leading to formation of pantaloon hernia [9]. A double hernia may not always be a pantaloon hernia but can also be present due to two indirect hernial sacs. There have been reports of these findings previously and hence, a deeper dissection and identification of the inguinal structures and canal is of utmost importance during hernia surgery. Misidentification or incomplete ligation of sac can lead to recurrence [10].

Pantaloon hernia clinically is seen almost exclusively in males and is identified by 2 distinct swellings in the inguinal region, one each medial and lateral to the pubic tubercle. In some cases, however, one of the hernias maybe occult and not present clinically but identified intra-operatively. The management, however does not change but only involves adequate repair of both the defects [10].

Although there are several hernia classification systems, perhaps, the Nyhus classification and Gilbert classification are the only ones (including the more recent European Hernia System) that may be assumed to consider pantaloon hernia as one of the subtypes, viz.

Type 3b and Type 6 respectively, once again underscoring the rarity of the condition in both genders.

Hernia surgery has always been the area of interest of the general surgeon and a constantly evolving field. All techniques of repair in the past consisted of tissue closure with variations which lead to tension in the suture lines and high recurrence rates. The advent of mesh repair with tension-free hernioplasty lead to dramatic change in practice. Laparoscopic repairs have been the most recent development with minimal scarring but require a steep learning curve [11,12]. There has been a significant discussion all over the world regarding hernia surgery and formation of a team of team of experts from various centres to develop guidelines for hernia surgery. The Herniasurge group guidelines state that groin hernia surgery can be done either open by Lichtenstein tension free mesh repair or Laparo-endoscopic mesh repair depending on the surgical expertise and local factors [13]. There have been no specific recommendations for pantaloon hernia repair. The international EndoHernia Society (IEHS) has developed a set recommendations based on meta analysis and expert opinions for both TAPP and TEP repairs but even those do not specify any for pantaloon hernia [14]. This may be due to the uncommon nature of pantaloon hernia and similar treatment as other inguinal hernias [13,14]. However, the practice for repair of pantaloon hernia is the same as for repair of other inguinal hernias in adults. Both open and laparoscopic techniques are used. Non-mesh repairs are not recommended due to lesser evidence is more chances of recurrence. Open repairs are preferred where the surgical expertise for laparoscopy and cost constraints are present [15].

4. CONCLUSION

In conclusion, direct inguinal hernias do occur in women albeit very rarely while pantaloon hernias are extremely rare and when present, may be associated with the testicular feminisation syndrome in young children. When present, pantaloon hernia in women should be treated with ligation and division of the round ligament of the uterus, obliteration of the canal of Nuck and mesh hernioplasty. The present case is reported with the purpose of documenting the extreme rarity of pantaloon hernia in adult women in the existing scientific literature.

CONSENT

All authors declare that written informed consent was obtained from the patient for publication of this case report and accompanying images.

ETHICAL APPROVAL

As per international standard or university standard written ethical permission has been collected and preserved by the authors.

COMPETING INTERESTS

Authors have declared that no competing interests exist.

REFERENCES

1. Perry CP, Echeverri JDV. Hernias as a cause of chronic pelvic pain in women. *JLS J Soc Laparoendosc Surg Soc Laparoendosc Surg*. 2006;10(2):212–5.
2. Chawla S. Inguinal hernia in females. *Med J Armed Forces India*. 2001;57(4):306–8.
3. Kark AE, Kurzer M. Groin hernias in women. *Hernia*. 2008;12(3):267–70.
4. Ofili OP. Possibilities of the strong posterior wall of inguinal canal in women. *Cent Afr J Med*. 1990;36(12):300–4.
5. Ando H, Kaneko K, Ito F, Seo T, Ito T. Anatomy of the round ligament in female infants and children with an inguinal hernia. *Br J Surg*. 1997;84(3):404–5.
6. Glassow F. An evaluation of the strength of the posterior wall of the inguinal canal in women. *Br J Surg*. 1973;60(5):342–4.
7. Rosen A, Nathan H, Luciansky E, Orda R. The inguinal region: Anatomic differences in men and women with reference to hernia formation. *Acta Anat (Basel)*. 1989;136(4):306–10.
8. Basrur G. Bilateral inguinal hernias containing ovaries. *Clinics and Practice*. 2015;5:708.
9. Rutkow IM, Robbins AW. Classification systems and groin hernias. *Surg Clin North Am*. 1998;78(6):1117–27.
10. Jones RG, Livaditis I, Almond PS. An unexpected finding during an inguinal herniorrhaphy: Report of an indirect hernia with two hernia sacs. *J Pediatr Surg Case Rep*. 2013;1(10):331–2.
11. Sakorafas GH, Halikias I, Nissotakis C, Kotsifopoulos N, Stavrou A, Antonopoulos C, et al. Open tension free repair of inguinal hernias; the Lichtenstein technique. *BMC Surg*. 2001;1:3.
12. Kulacoglu H. Current options in inguinal hernia repair in adult patients. *Hippokratia*. 2011;15(3):223–31.
13. International guidelines for groin hernia management. *Hernia*. 2018;22(1):1–165.
14. Bittner R, Arregui ME, Bisgaard T, Dudai M, Ferzli GS, Fitzgibbons RJ, et al. Guidelines for laparoscopic (TAPP) and endoscopic (TEP) treatment of inguinal Hernia [International Endohernia Society (IEHS)]. *Surg Endosc*. 2011;25(9):2773–843.
15. Pahwa HS, Kumar A, Agarwal P, Agarwal AA. Current trends in laparoscopic groin hernia repair: A review. *World J Clin Cases WJCC*. 2015;3(9):789–92.

© 2018 Choudhari et al.; This is an Open Access article distributed under the terms of the Creative Commons Attribution License (<http://creativecommons.org/licenses/by/4.0>), which permits unrestricted use, distribution, and reproduction in any medium, provided the original work is properly cited.

Peer-review history:
The peer review history for this paper can be accessed here:
<http://www.sciencedomain.org/review-history/26808>