

# Shoulder and Upper Arm Surgery Anaesthesia with Interscalene Approach of Brachial Block and Sedation versus Same Method Adjunct with Additional Suprascapular Nerve Block: A Randomised Controlled Study

SURAJIT CHATTOPADHYAY<sup>1</sup>, HIRAK BISWAS<sup>2</sup>, ANINDYA MUKHERJEE<sup>3</sup>, SANDIP ROYBASUNIA<sup>4</sup>, SUDIPTA SAHA<sup>5</sup>, LEENA BHOWMICK<sup>6</sup>, ANJAN DAS<sup>7</sup>, SUBRATA KUMAR MANDAL<sup>8</sup>



## ABSTRACT

**Introduction:** Interscalene Brachial Plexus Block (ISBPB) provides optimal analgesia for shoulder and upper arm surgery. However, higher incidence of phrenic nerve palsy limits the application of ISBPB for patients with limited pulmonary reserve. The Supplemented Suprascapular Nerve Block (SSNB) is a landmark based technique that is believed to block the sensory fibres supplying major part of shoulder joint, as well as, supraspinatus and infraspinatus muscles.

**Aim:** To compare the analgesic effect and duration of sensory block in interscalene versus interscalene with SSNB block for shoulder and upper arm surgery.

**Materials and Methods:** This double-blinded randomised controlled study was conducted in a Tertiary Care Institute, from April 2021 to March 2022. Eighty patients posted for shoulder and upper arm surgery were divided into two equal groups (group A and B). In group A (n=40), 30 mL 0.5% levobupivacaine in ISBPB and in group B (n=40), 15 mL 0.5% levobupivacaine in ISBPB+15 mL 0.5% levobupivacaine in SSNB were administered. Demographic data, sensory and motor block, onset times and durations, time to administer first rescue

analgesic, total analgesic requirement, indications of upper arm surgeries, surgical bleeding and surgeon's satisfaction score, postoperative Visual Analogue Scale (VAS) score were recorded for each patient.

**Results:** The onset and duration of sensory and motor block was significantly faster and longer in group B. Consequently, time to administer first rescue analgesic in group A vs group B (325.88±33.23 vs. 348.34±37.12, respectively) minutes were significantly delayed and lesser in amount in group B. On the other hand, suprascapular block reduced the odds of block-related respiratory (group A vs group B are 14 and 10, respectively) complications. In group B postoperative VAS score at 24 hour was significantly lower (p-value <0.05) than group A was (3.5 vs 4.5). Intraoperative haemodynamic parameters were comparable among two groups throughout the study period.

**Conclusion:** SSNB when supplemented with Interscalene Block (ISB) could be an effective adjunct for shoulder and upper arm surgery. This combination prolongs the sensory blockade duration, reduces requirement of analgesics and side-effects in postoperative period.

**Keywords:** Interscalene brachial plexus block, Rescue analgesic, Visual analogue scale

## INTRODUCTION

Shoulder and upper arm surgery are associated with acute postoperative pain with fair number of cases reported severe pain in the immediate postoperative period [1]. Interscalene Nerve Block (ISB) has potentiality to serve as sole anaesthesia technique as well as to offer effective analgesia for shoulder and upper arm surgery. It decreases immediate postoperative pain scores and lowers opioid consumption in postoperative period [2]. It anaesthetises the caudal portion of the cervical plexus (C3, C4) and the superior (C5, C6) and middle (C7) trunks of the brachial plexus. ISB is associated with various complications. Among which most common is phrenic nerve palsy, almost in all cases undergoing conventional techniques [3,4]. Other serious complications are pneumothorax, brachial plexus injury, extended motor block, inadvertent epidural anaesthesia and vertebral artery injection [5,6].

Like ultrasound or nerve locator guidance, the purpose of reducing local anaesthetics dose and thereby reducing chances of complications, keeping satisfactory efficacy of block; researchers examine several options, but not restricted to the SSNB [7-9]. The SSNB technique is a simple, superficial landmarked based technique that is believed to block the sensory fibres supplying major

part of shoulder joint, as well as supraspinatus and infraspinatus muscles. Studies comparing the efficacy of ISB and SSNB show mixed response in shoulder and upper arm procedure [10-13]. In this regard, some studies show ISB as superior than SSNB, whereas few studies observed both of the method is of same efficacy [14].

The present study was designed to evaluate the efficacy of ISB alone in one group and compare it with ISB supplemented with SSNB in another group, who underwent shoulder and upper arm surgery. First rescue analgesic requirement between two groups were the main primary variable. Onset and duration of sensory and motor block, requirement of diclofenac sodium as rescue analgesic drug were the secondary outcome measures.

## MATERIALS AND METHODS

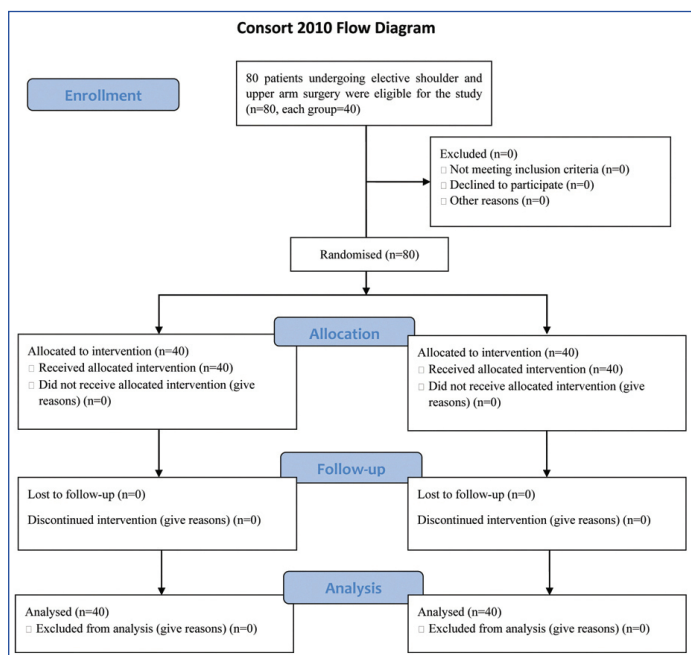
This double-blinded randomised controlled study was conducted in a Tertiary Care Institute, from April 2021 to March 2022, after obtaining permission from the Institutional Ethics Committee (Number-CMSDH/IEC/227/03-2021), and written informed consent was taken from every enrolled patients.

**Inclusion criteria:** A total of 80 adult patients of either sex aged between 30 to 50 years of ASA status I and II scheduled to undergo

different uncomplicated orthopaedic surgeries of upper arm and shoulder where duration of surgery, anaesthesia and surgery is expected to be less than two hours were included in the study.

**Exclusion criteria:** Pregnancy, lactating mothers, hepatic, renal or cardiopulmonary abnormality, alcoholism, diabetes, long-term analgesic therapy, bleeding diathesis and local skin site infections were excluded from the study. Also, patients having a history of significant neurological, psychiatric, or neuromuscular disorders were also excluded from the study.

All patients were randomly allocated to two equal groups (n=40 in each group) using computer-generated random number list. Patients in group A received 30 mL 0.5% levobupivacaine for ISB and group B received 15 mL 0.5% levobupivacaine for ISB and 15 mL of 0.5% levobupivacaine for SSB [Table/Fig-1].



**[Table/Fig-1]:** Consolidated Standards of Reporting Trials (CONSORT) flowchart.

## Study Procedure

In the preoperative check-up, patients were enquired about operative history, drug intake history. Airway examination was done in every patient along with general and systemic examinations. Patients were confirmed about overnight (from midnight) fasting and sedative premedication with alprazolam. H2 blocker is given at night and two hour before surgery. VAS was explained twice in preoperative night and preoperative check-up clinic. After receiving the patients in the preoperative holding area, each patient was attached with standard multipara monitor and Ringer's lactate infusion was started. ISB was administered with insulated 22G, Stimuplex® needle with (output current <0.5 mA) 30 mL local anaesthetic solution was injected in group A. In group B in addition to ISB with 15 mL drug, Suprascapular block was performed with 15 mL of 0.5% levobupivacaine with the same needle.

Motor and sensory anaesthesia was tested at every two minutes interval for the first 30 minutes, then every half hourly for 10 hours. Pinprick and complete muscle paralysis was tested for sensory and block assessment, respectively. Sensory block duration was identified as the time gap from the onset of sensory block to the first postoperative pain. Similarly, motor block duration was identified as the time gap between starting of motor block and complete recovery of motor block.

For sensory loss assessment, pin prick test was used: 0- no effect; 1- analgesia (loss of pin-prick sensation); 2- loss of touch in the distribution of median; ulnar and radial nerve. Motor blockade was evaluated based on modified Bromage scale: 3=elbow flexion against gravity force; 2=wrist flexion against gravity force;

1=finger movement; and 0=no motion. Surgery commenced after 30 minutes, if the block was considered to be adequate, Injection diclofenac sodium 75 mg was given intramuscularly when VAS  $\geq 3$  cm. The number of injection fentanyl given to each patient during first 24 hour of the postoperative period was recorded.

Surgeons were kept unaware about the anaesthesia (block) technique used and they were asked to assess the dryness of operative field at every half hourly interval and the scale for this assessment was based on scores from 0 to 5 (Likert scale) [15]. 0=No Bleeding; 1=Minor bleeding, no aspiration required; 2=Minor bleeding, aspiration required; 3=Minor bleeding, frequent aspiration required; 4=Moderate bleeding; visible only with aspiration; 5=Severe bleeding, frequent aspiration required, very hard to perform surgery. In all the operations every half hour interval reading was taken and last reading was taken just before starting of closure (at end of surgery).

Surgeon's satisfaction score (1=Bad; 2=Moderate; 3=Good; 4=Excellent) which was used here was previously been used in other studies [16].

## STATISTICAL ANALYSIS

Estimated first rescue analgesic requirement time in each group was 340 minutes after a crossover pilot study of 10 patients. Sample size calculation was done by using the time for application of first pain medicine. For creating a 10% difference with  $p < 0.05$ , the required sample size was 38 per group, considering SD as the 35 minutes [2]. In the present study, 40 patients were enrolled in each group. Data was analysed using Statistical Package for the Social Sciences software (version 18.0). Pearson's Chi-square test was used for analysing the categorical variables. Categorical variables Independent sample t-test was used for analysing normally distributed quantitative variables and  $p$ -value  $< 0.05$  was considered statistically significant.

## RESULTS

The age, sex distribution, body weight, height, American Society of Anaesthesiologists (ASA) status, and duration of surgery in the two groups were found to be comparable among two groups [Table/Fig-2]. The indications for upper arm surgeries were quite comparable in both groups [Table/Fig-3]. The onset of both sensory and motor blocks was earlier in group B [Table/Fig-4]. Also, motor and sensory block durations were statistically longer in the group B (ISB and SSNB) than group A (ISB) [Table/Fig-4]. In group B, postoperative VAS score at 24 hour was significantly lower ( $p$ -value  $< 0.05$ ) than group A was (3.5 vs 4.5). The mean duration of analgesia was 348.34 minutes in group B, but 325.88 minutes in the group A [Table/Fig-5]. Group B required less amount of diclofenac injection as rescue analgesics than patients in group A (ISB) in first 24 hour of postoperative period ( $p$ -value  $< 0.05$ ).

[Table/Fig-6] Surgical bleeding score was significantly higher in group A than group B. Less bleeding and excellent operative condition, Surgeon's satisfaction score was significantly better in group B than group A [Table/Fig-6].

[Table/Fig-7] shows that the side-effects were quite comparable among two groups but less in group B.

Parameters	Group A (n=40)	Group B (n=40)	p-value
Age (years)	41.23 $\pm$ 4.9	39.94 $\pm$ 3.7	0.1878
Body weight (kg)	59.72 $\pm$ 6.10	62.34 $\pm$ 6.9	0.0963
Sex (Male/Female)	30 (75%);10 (25%)	33 (82.5%);7 (17.5%)	0.0756
Height (cm)	160.91 $\pm$ 12.12	162.14 $\pm$ 13.21	0.6655
ASA physical status (I/II)	35 (87.5%)/5 (12.5%)	37 (92.5%)/3 (7.5%)	0.2299
Surgery time (min)	85.60 $\pm$ 7.8	89.10 $\pm$ 8.02	0.0514
Tourniquet time (min)	72.86 $\pm$ 6.8	75.46 $\pm$ 7.10	0.0984

**[Table/Fig-2]:** Comparison of demographic data. Values in the groups are presented as Mean $\pm$ SD.

Indications for upper limb surgery	Group A (n=40)	Group B (n=40)
Shoulder hemiarthroplasty	6 (15%)	8 (20%)
Shoulder arthroscopy	15 (37.5%)	13 (32.5%)
Sub acromial decompression	7 (17.5%)	9 (22.5%)
Rotator cuff repair	8 (20%)	6 (15%)
Fracture shaft humerus	4 (10%)	4 (10%)

**[Table/Fig-3]:** Comparison of upper arm surgeries. Data are n (%).

Parameters	Group A (n=40)	Group B (n=40)	p-value
Onset time for sensory blockade (min)	20.86±2.54	19.56±2.10	0.0147
Onset time for motor blockade (min)	27.22±3.10	25.86±2.88	0.0455
Duration of sensory blockade (min)	310.46±30.10	342.48±32.56	0.0001
Duration of motor blockade (min)	232.56±21.72	260.92±21.84	0.0001

**[Table/Fig-4]:** Onset time and duration (min) for sensory and motor block.

Variable	Group A (n=40)	Group B (n=40)	p-value
Request of 1 <sup>st</sup> analgesic (min)	325.88±33.23	348.34±37.12	0.0157
Total rescue analgesia as diclofenac sodium (mg)	102.46±10.08	88.22±9.34	0.0001

**[Table/Fig-5]:** Requirement of rescue analgesic drug in postoperative period (Time and number of intramuscular diclofenac injection). p-value <0.05 considered significant

Variable	Group A n (%)	Group B n (%)	p-value
<b>Operative bleeding score (%)</b>			
0=No Bleeding	2 (5)	1 (2.5)	0.0008
1=Minor bleeding, no aspiration required	20 (50)	15 (37.5)	
2=Minor bleeding, aspiration required	12 (30)	17 (42.5)	
3=Minor bleeding, frequent aspiration required	4 (10)	2 (5)	
4=Moderate bleeding, visible only with aspiration	1 (2.5)	4 (10)	
5=Severe bleeding, frequent aspiration required, very hard to perform surgery	1 (2.5)	1 (2.5)	

Variable	Group A n (%)	Group B n (%)	p-value
<b>Surgeon's satisfaction score (%)</b>			
1=Bad	1 (2.5)	3 (7.5)	0.0006
2=Moderate	3 (7.5)	6 (15)	
3=Good	10 (25)	14 (35)	
4=Excellent	24 (60)	17 (42.5)	

**[Table/Fig-6]:** Operative bleeding score and surgeon's satisfaction score. p-value <0.05 considered significant

Parameters	Group A (n=40)	Group B (n=40)	p-value
Respiratory depression	14	10	0.1441
Sedation	9	5	0.0558
Pruritus	6	4	0.2918

**[Table/Fig-7]:** Side-effects.

## DISCUSSION

The Supplemented Suprascapular Nerve Block (SSNB) is safe and efficacious technique in pain management of degenerative diseases of shoulder as well as additional procedure in surgical anaesthesia for upper arm and shoulder joint surgery and postoperative pain management. So, it was hypothesised that SSNB could be an effective adjunct with Interscalene approach of brachial plexus block (ISB) for upper arm surgery anaesthesia. So, the study aimed to examine the efficacy of SSNB with adjunct to ISB and to compare the sedative requirement for sole anaesthetic technique as well as early postoperative pain control for upper arm surgery in comparison with ISB alone. Levobupivacaine, being less cardiac and neurotoxic, was used in the study for administering ISB as well

as in SSNB with ISB to manage intra and postoperative pain for upper arm surgery [17-21].

A study on the efficacy and respiratory consequences of ultrasound guided ISB was conducted by Riazi S et al., in 40 patients yielded similar results [Table/Fig-1] [8]. It is evident that the mean duration of surgery and tourniquet time were almost comparable in both the groups with no statistically significant difference. From [Table/Fig-2], it is found that indications of surgical procedures were almost similar in both the groups and had no statistical significance.

The onset time of sensory block in group B was faster than in group A. Hussain N et al., also found similar results for onset of motor block in SSNB versus ISB [22]. They also compared the analgesic effect and safety of suprascapular block versus ISB for shoulder surgery and found ISB to have a significantly longer duration of analgesia than SSB but the side-effects of ISB were higher than SSB. Again, SSB needed more rescue analgesic than ISB but the result was not statistically significant. In the present study, the group ISB (group A) required an early rescue analgesia and in a higher total dose than SSB (group B).

In the present study, the duration of sensory block in SSB group was significantly longer. The duration of motor block in SSB group was also more and the result was also significantly longer in combined group (SSB) than in the ISB group. So SSB group showed better results than ISB group. Though a meta-analysis concluded that ISB more efficiently control postoperative pain but side-effects are higher in this group and so they suggested that suprascapular block may be considered an effective and safe ISB alternative for shoulder surgery [22].

Duration of analgesia was found to be significantly prolonged in ISB with suprascapular SSB combined group than ISB only group. Addition of axillary block with SSNB leads to a superior alternative to ISB for analgesia in shoulder surgeries while combined with general anaesthesia [23-25].

In the present study, patients of ISB and SSB combined group required significantly a smaller number of diclofenac sodium injection in first 24 hours of postoperative period than the patients of ISB group. Although Hussain N et al., described that regarding opioid use for postoperative pain relief, SSNB technique is not different for ISB [22]. Both the groups showed similar side-effects for opioids, duration of pain relief, postanaesthesia recovery room pain killer consumption and discomfort associated with anaesthesia procedure.

It was found that hemi-diaphragmatic paraesis, perioral numbness, residual neurodeficit among both the study groups but the incidence was quite comparable among two groups (p-value >0.05). Riazi S et al., found the incidence of diaphragmatic paralysis was significantly lower in the low-volume group (group B in the present study, 15 mL) compared with the standard-volume group (group B in the present study, 30 mL) (45% vs 100%) [8]. Fall in Forced Expiratory Volume (FEV), Forced Vital Capacity (FVC) and Peak Expiratory Flow Rate (PEFR) at half hour after the administration of block was also statistically significantly reduced in the low-volume group. In addition, they also found a significantly greater decrease in postoperative oxygen saturation in the standard-volume group after surgery [26]. Total morphine use, pain score and quality of sleep were quite similar among two groups. Sedation due to proposed sedative was almost equal in both the groups, but it was quite arousable and did not cause any respiratory depression. Riazi S et al., observed that ultrasound guided ISB with lower quantity drug produced less phrenic nerve weakness and other complications [8].

Keeping the operating surgeon constant and scoring of surgical site was done with a 6-point scale for dryness and bleeding at every five minute interval. Surgeon's satisfaction was scored by the same surgeon with a 4-point scale. Levobupivacaine dose was chosen as per recommendation in the text book [27]. The drug dose used was same as used by previous researchers. To



be on a safer side, the drug volume which was used was slightly less. The study was conducted with 30 mL of local anaesthetic for successful ISB in group A, knowing that it will affect phrenic nerve roots leading to inadvertent hemi-diaphragmatic paraesis. Due to large volume perioral numbness, residual neuro-deficit were also more in group A. In the 2<sup>nd</sup> group, group B (30=15+15) mL drug was equally distributed in interscalene and suprascapular groove having promising results in all aspects.

### Limitation(s)

The study compared ISB with ISB plus SSB based on their known optimal, as well as, safe local anaesthetic doses (single shot) for upper arm surgeries without the knowledge of local anaesthetic pharmacodynamic change in doses. Again, blinding was not properly followed because the two injection sites were different.

### CONCLUSION(S)

The Supplemented Suprascapular Nerve Block (SSNB) is safe and efficacious technique in pain management of degenerative shoulder diseases, as well as, additional procedure in surgical anaesthesia for upper arm and shoulder surgery and postoperative pain management. Hence, the authors also conclude that, SSNB could be an effective adjunct with interscalene approach of brachial plexus block (ISB) for upper arm surgery anaesthesia, prolonging the duration of sensory and motor blockade, reducing the requirement of rescue analgesic in postoperative period, by reducing the load of appreciable side-effect.

### REFERENCES

- [1] Kumara AB, Gogia AR, Bajaj JK, Agarwal N. Clinical evaluation of post-operative analgesia comparing suprascapular nerve block and interscalene brachial plexus block in patients undergoing shoulder arthroscopic surgery. *J Clin Orthop Trauma*. 2016;7(1):34-39.
- [2] Abdallah FW, Halpern SH, Aoyama K, Brull R. Will the real benefits of single-shot interscalene block please stand up? A systematic review and meta-analysis. *Anaesth Analg*. 2015;120(5):1114-11.
- [3] Brown AR, Weiss R, Greenberg C, Flatow EL, Bigliani LU. Interscalene block for shoulder arthroscopy: Comparison with general anaesthesia. *Arthroscopy*. 1993;9(3):295-300.
- [4] Urmev WF, Talts KH, Sharrock NE. One hundred percent incidence of hemidiaphragmatic paresis associated with interscalene brachial plexus anaesthesia as diagnosed by ultrasonography. *Anaesth Analg*. 1991;72(4):498-503.
- [5] Fujimura N, Namba H, Tsunoda K, Kawamata T, Taki K, Igarasi M, et al. Effect of hemidiaphragmatic paresis caused by interscalene brachial plexus block on breathing pattern, chest wall mechanics, and arterial blood gases. *Anaesth Analg*. 1995;81(5):962-66.
- [6] Lenters TR, Davies J, Matsen FA 3<sup>rd</sup>. The types and severity of complications associated with interscalene brachial plexus block anaesthesia: Local and national evidence. *J Shoulder Elbow Surg*. 2007;16(4):379-87.
- [7] Renes SH, van Geffen GJ, Rettig HC, Gielen MJ, Scheffer GJ. Minimum effective volume of local anaesthetic for shoulder analgesia by ultrasound-guided block at root C7 with assessment of pulmonary function. *Reg Anaesth Pain Med*. 2010;35(6):529-34.
- [8] Riazi S, Carmichael N, Awad I, Holtby RM, McCartney CJ. Effect of local anaesthetic volume (20 vs 5 ml) on the efficacy and respiratory consequences of ultrasound-guided interscalene brachial plexus block. *Br J Anaesth*. 2008;101(4):549-56.
- [9] Shin SW, Byeon GJ, Yoon JU, Ok YM, Baek SH, Kim KH, et al. Effective analgesia with ultrasound-guided interscalene brachial plexus block for postoperative pain control after arthroscopic rotator cuff repair. *J Anaesth*. 2014;28(1):64-69.
- [10] Raj PP. Suprascapular nerve block. In: Waldman SD, editor. *Pain Management*. 2<sup>nd</sup> Ed. Philadelphia: WB. Saunders; 2007. pp. 1239-42.
- [11] Ko SH, Cho SD, Lee CC, Choi JK, Kim HW, Park SJ, et al. Comparison of arthroscopically guided suprascapular nerve block and blinded axillary nerve block vs. blinded suprascapular nerve block in arthroscopic rotator cuff repair: A randomised controlled trial. *Clin Orthop Surg*. 2017;9(3):340-47.
- [12] Pitombo PF, Meira Barros R, Matos MA, Pinheiro Mólolo NS. Selective suprascapular and axillary nerve block provides adequate analgesia and minimal motor block. Comparison with interscalene block. *Braz J Anaesthesiol*. 2013;63(1):45-51.
- [13] Patil KN, Singh ND. Clonidine as an adjuvant to ropivacaine-induced supraclavicular brachial plexus block for upper limb surgeries. *J Anaesthesiol Clin Pharmacol*. 2015;31(3):365-69.
- [14] Fortier J, Chung F, Su J. Predictive factors of unanticipated admission in ambulatory surgery: A prospective study. *Anaesthesiology*. 1996;85:A27.
- [15] Jouybar R, Nemati M, Asmari N. Comparison of the effects of remifentanyl and dexmedetomidine on surgeon satisfaction with surgical field visualization and intraoperative bleeding during rhinoplasty. *BMC Anaesthesiol*. 2022;22:24.
- [16] Das A, Biswas H, Mukherjee A, Basunia SR, Chhaule S, Mitra T, et al. Evaluation of preoperative flupirtine in ambulatory functional endoscopic sinus surgery: A prospective, double-blind, randomised controlled trial. *Anaesth Essays Res*. 2017;11(4):902-08.
- [17] Foster RH, Markham A. Levobupivacaine: A review of its pharmacology and use as a local anaesthetic. *Drugs*. 2000;59:551-79.
- [18] Crews JC, Foreman AS, Weller RS, Moss JR, Tucker SP. Onset, duration, and dose tolerability of levobupivacaine 0.5% for axillary brachial plexus neural blockade. *Anaesthesiology*. 1998;89:A894.
- [19] Cox CR, Checketts MR, Mackenzie N, Scott NB, Bannister J. Comparison of S(-) bupivacaine with racemic (RS)-bupivacaine in supraclavicular brachial plexus block. *Br J Anaesth*. 1998;80:594-98.
- [20] Klein SM, Nielsen KC. Brachial plexus blocks: Infusions and other mechanisms to provide prolonged analgesia. *Curr Opin Anaesthesiol*. 2003;16:393-99.
- [21] Axelsson K, Gupta A. Local anaesthetic adjuvants: Neuraxial versus peripheral nerve block. *Curr Opin Anaesthesiol*. 2009;22:649-54.
- [22] Hussain N, Goldar G, Ragina N, Banfield L, Laffey JG, Abdallah FW. Suprascapular and interscalene nerve block for shoulder surgery: A systematic review and meta-analysis. *Anaesthesiology*. 2017;127(6):998-1013.
- [23] Sripada R, Bowens C. Regional anaesthesia procedures for shoulder and upper arm surgery upper extremity update—2005 to present. *International Anaesthesiology Clinics*. 2012;50(1):26-46.
- [24] Price DJ. The shoulder block: A new alternative to interscalene brachial plexus blockade for the control of postoperative shoulder pain. *Anaesth Intensive Care*. 2007;35(4):575-81.
- [25] Checucci G, Allegra A, Bigazzi P, Gianesello L, Ceruso M, Gritti G. A new technique for regional anaesthesia for arthroscopic shoulder surgery based on a suprascapular nerve block and an axillary nerve block: An evaluation of the first results. *Arthroscopy*. 2008;24(6):689-96.
- [26] Berde CB, Strichartz GR. Local Anaesthetics. In: Miller RD, Cohen NH, Eriksson LI, Fleisher LA, Wiener-Kronish JP, Young WL, editors. *Miller's Anaesthesia*. 8<sup>th</sup> ed. Philadelphia: Elsevier Saunders; 2010. Pp. 1028-55.
- [27] Ambi U, Bhanupriya P, Hulkund SY, Prakashappa DS. Comparison between perivascular and perineural ultrasound-guided axillary brachial plexus block using levobupivacaine: A prospective, randomised clinical study. *Indian J Anaesth*. 2015;59:658-63.

#### PARTICULARS OF CONTRIBUTORS:

1. Associate Professor, Department of Anaesthesiology, Institute of Post Graduate Medical Education and Research, Kolkata, West Bengal, India.
2. Assistant Professor, Department of Anaesthesiology, College of Medicine and Sagore Dutta Hospital, Kolkata, West Bengal, India.
3. Associate Professor, Department of Anaesthesiology, NRS Medical College and Hospital, Kolkata, West Bengal, India.
4. Associate Professor, Department of Anaesthesiology, Diamond Harbour Government Medical College and Hospital, Diamond Harbour, West Bengal, India.
5. Postgraduate Trainee, Department of Anaesthesiology, College of Medicine and Sagore Dutta Hospital, Kolkata, West Bengal, India.
6. Postgraduate Trainee, Department of Anaesthesiology, College of Medicine and Sagore Dutta Hospital, Kolkata, West Bengal, India.
7. Professor, Department of Anaesthesiology, College of Medicine and Sagore Dutta Hospital, Kolkata, West Bengal, India.
8. Professor and Head, Department of Anaesthesiology, College of Medicine and Sagore Dutta Hospital, Kolkata, West Bengal, India.

#### NAME, ADDRESS, E-MAIL ID OF THE CORRESPONDING AUTHOR:

Dr. Sandip Roybasunia,,  
13, Diamond Harbour Road, Kolkata-700038, West Bengal, India.  
E-mail: drroybasunia@gmail.com

#### PLAGIARISM CHECKING METHODS: [Jain H et al.]

- Plagiarism X-checker: Aug 07, 2022
- Manual Googling: Nov 26, 2022
- iThenticate Software: Dec 06, 2022 (12%)

#### ETYMOLOGY: Author Origin

#### AUTHOR DECLARATION:

- Financial or Other Competing Interests: None
- Was Ethics Committee Approval obtained for this study? Yes
- Was informed consent obtained from the subjects involved in the study? Yes
- For any images presented appropriate consent has been obtained from the subjects. NA

Date of Submission: **Aug 06, 2022**  
Date of Peer Review: **Oct 08, 2022**  
Date of Acceptance: **Dec 16, 2022**  
Date of Publishing: **Mar 01, 2023**