



## Replantation of Knocked out Teeth after Traumatic Avulsion

Shirin Sultana Chowdhury<sup>1</sup>, Md Nazmul Hasan<sup>2\*</sup> and Rumana Afroz<sup>1</sup>

<sup>1</sup>Department of Conservative Dentistry and Endodontics, Update Dental College, Dhaka, Bangladesh.

<sup>2</sup>Department of Orthodontics, School of Dental Sciences, Universiti Sains Malaysia, Kelantan, Malaysia.

### Authors' contributions

This work was carried out in collaboration between all authors. Author SSC performed the clinical work, draft the manuscript. Author MNH managed the literature searches, checked the draft, analyses of the study performed and prepare the final manuscript. Author RA provide management to the patient as primary dental officer and assis, author SSC to record all document. All authors read and approved the final manuscript.

### Article Information

DOI: 10.9734/BJMMR/2015/17710

#### Editor(s):

(1) Yoshiro Fujii, Manager of Shin Kobe Dental Clinic, Japan.

#### Reviewers:

(1) Anonymous, University of Coimbra-PT, Portugal.

(2) Marcos Cezar Ferreira, Universidade Severino Sombra, Faculdade de Odontologia de Vassouras, Brazil.

Complete Peer review History: <http://www.sciencedomain.org/review-history.php?iid=1118&id=12&aid=9169>

Case Study

Received 25<sup>th</sup> March 2015  
Accepted 18<sup>th</sup> April 2015  
Published 8<sup>th</sup> May 2015

### ABSTRACT

Management of permanent tooth avulsion often challenging for dental practitioner, as avulsion resulting complete exfoliation of tooth from its socket, is usually associated with damage to the supporting structures. Managing the edentulous area to improve aesthetics, phonetics, function is better achieved by replanting the avulsed tooth rather than prosthesis. This article report a case avulsed tooth management of 12-year-old-girl due to accidental knocked out of both central incisors. Immediate after injuries patient report to the emergency department over phone and asked to collect and keep the avulsed tooth sinking into milk. Patient was managed by dentist within 60 minutes of the accident and have follow-up by radiologically and clinically 1 year post accident. Replantation of tooth immediate after avulsion can be managed by replantation into its socket.

**Keywords:** Tooth replantation; tooth avulsion; athletic injuries; tooth injuries.

\*Corresponding author: Email: [nazmul2030@gmail.com](mailto:nazmul2030@gmail.com), [mnhasan@usm.my](mailto:mnhasan@usm.my);

## 1. INTRODUCTION

Traumatic injuries to teeth are common, with between 6-34% of children aged 8-15 experiencing damage to their permanent teeth [1]. One of the most severe dento-alveolar injuries is avulsion, where the tooth or teeth are completely knocked out of the mouth. This injury accounts for between 0.5 to 3% of dento-alveolar trauma to permanent teeth [2]. The active movement of children at this age group and relatively resilient alveolar bone with minimal resistance to extrusive forces might be reason behind this age group being affected children. An avulsed tooth is one that has been knocked out accidentally from the alveolar socket for a number of reasons: A blow to the mouth, accident involving the face or during contact sports. It is possible to replace the tooth in the socket successfully if the action is taken as soon as possible [3]. Certain predisposing factors like protruded maxillary incisors and insufficient lip closure may affect the extent of the dental trauma [2]. Healing with periodontal ligament (i.e. regeneration) after replantation will occur only if the innermost cell layer along the root surface is viable [4]. Clinical studies revealed that the prognosis is best for teeth replanted within 5 minutes after avulsion [2].

Prolonged non-surgical storage of avulsed teeth before replantation results in total necrosis of the periodontal ligament and healing by replacement root resorption (i.e. repair) becomes the only option [4]. Some characteristics of storage medium i.e. pH, osmolarity [5] and temperature should be compatible with the survival of periodontal ligament [6]. Storage media as milk, Hanks balanced salt solution and viaspan have been proved to maintain cell viability after long periods [7].

This article reports the case of accidentally knocked out of two maxillary central incisors that were kept in milk from the moment of trauma until its replantation within 60 minutes later. The successful clinical and radiographic findings observed after 12-months follow-up are described.

## 2. REPORT OF THE CASES

A 12-years-old-girl had an accidental fall down from stairs at her own house. Immediately her mother gave a phone call to the emergency section of the Update dental college and hospital,

Dhaka, upon instruction from the Dental officer her two knocked out incisors were kept sunk within milk. The endodontist attended her case within 60 minutes of the accident.

At initial examination laceration on the lip and clot on the socket of the teeth 12 and 21 noticed. (Fig. 1A) Teeth on the milk were found with intact pulp chamber with close root apex, however the crown fracture were noticed and patient's attendant was not able to present any fracture part of the crown. The patient was immediately anaesthetized, the alveolar socket was washed with saline and examined with a blunt instrument to check for the patency of the socket and to create fresh bleeding (Fig. 1B). Then both teeth were inserted into the respective alveolar socket to check the occlusion and alveolar patency (Figs. 1C, 1D). After revealing everything favorable both the teeth were removed from socket and then teeth were undergone extra oral endodontic treatment. The knocked out two maxillary central incisors were prepared by placing those we only immerse the teeth within tetracycline solution for 5 mins and replanted. Root canal were prepared with protaper hand instruments and obturated with gutta percha and zinc oxide eugenol sealer (Fig. 2). Then the knocked out maxillary central incisors were replanted back into the alveolar socket with finger pressure and checked the occlusion as previously marked.

The teeth were splinted to the adjacent teeth with composite resin and gingival laceration was dressed with povidone iodine solution. The patient was instructed about her biting habit and oral hygiene implement. A 7 days course of systemic penicillin was prescribed and the patient was referred for an anti-tetanus booster. The splint was removed 10 days later and the replanted teeth were restored with composite resin. Radiograph and clinical examination were performed during 12 months follow-up period. During the above mentioned period, the teeth remained in a stable functional position and did not reveal any clinical ankylosis or resorption (Fig. 3). Moreover, it remained functional stability and was aesthetically acceptable after 1 year follow-up (Fig. 4).

Both the patient and her parents were satisfied with the treatment outcome and wanted to avoid complicated treatment, so it was decided to further follow-up and keep the replanted teeth as long as possible.

### 3. DISCUSSION

Literature review reveal that the important factor to ensure a favorable outcome after replantation is the extraoral time elapsed between the injury and the replantation of tooth [2,4]. Most importantly care should be taken to the avulsed tooth to prevent from drying, which causes loss of normal physiologic metabolism and morphology of the periodontal ligament cells. [4] Aim is to replant a clean tooth with which means that the patient should be brought to the office immediately. If delay occurs in replantation, the tooth should be quickly stored in an appropriate medium until the patient can go the dental office for replantation. Suggested storage media in order of preference are: Milk, saliva (either in the vestibule of the mouth or in a container into which the patients spits), physiologic saline or water [4]. Water is the least desirable storage medium because the hypotonic environment causes rapid lysis and increased inflammation [8]. Hank's balanced salt solution has shown the superior ability in maintaining viability of the periodontal ligament fibers for extended periods [9]. However, they are presently impractical as they are not generally available at accident site.

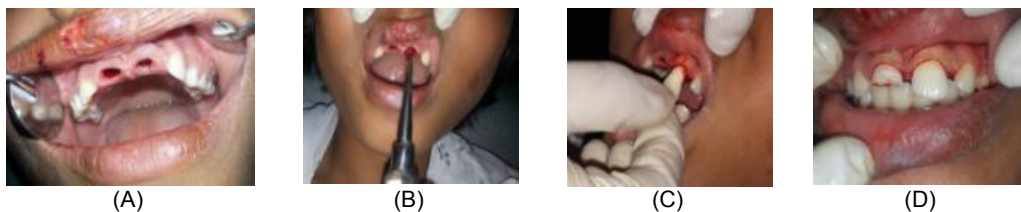Irrespective of the root surface treatment, there is consensus in the literature in that replanted teeth should be treated endodontically because the necrotic pulp and its toxins affect the periodontal ligament cells through the dentinal tubules and play a decisive role in the root resorption process [9-11]. Some operator suggest that, If extra oral dry time exit 60 minutes in a closed apex the teeth should be treated endodontically outside the oral cavity [11]. Another aspect of replantation is the preparation of socket which consists of removal of destructions as blood clots and bone fragments in order to facilitate the replantation.

The goal of antibiotic therapy is to avoid bacterial proliferation in the area of ongoing process and contribute to the prevention of inflammatory

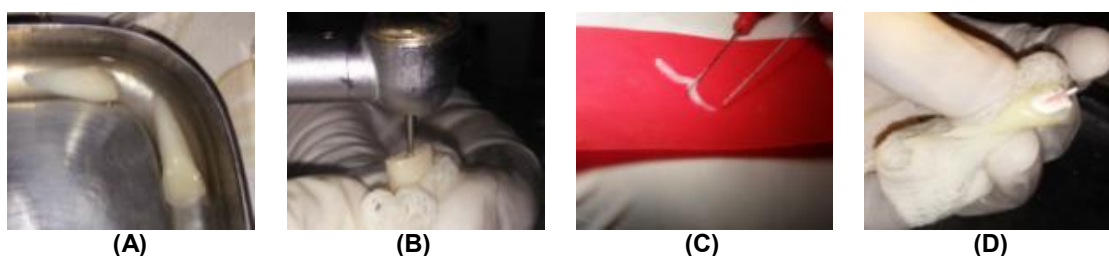
resorption. Ideally a broad spectrum antibiotic should be administered for seven days [12]. It is necessary to splint the replanted tooth to the adjacent teeth flexibly during 7-10 days for periodontal healing and then to perform root canal treatment to prevent the inflammatory root resorption in case of immediate replantation of tooth with closed apex.

In our presented case, the avulsed incisors had close apices and were kept in milk from the moment of trauma until its replantation 60 minutes later. Prolonged extra oral time and closed apices were the factors that cause deficiency of pulpal and periodontal healing, so it was assumed that the prognosis will be negligible. But, in 12 months follow-up showed maintenance of root integrity, intact lamina dura and absent of tooth mobility, which are indicative of successful replantation. Moreover, It was aimed to prevent the teeth loss, maintain aesthetic and functional properties as well as allowing the alveolar bone growth. To achieve the goal of the treatment, the knocked out teeth were replanted back into the socket into its original position and splinted for 10 days.

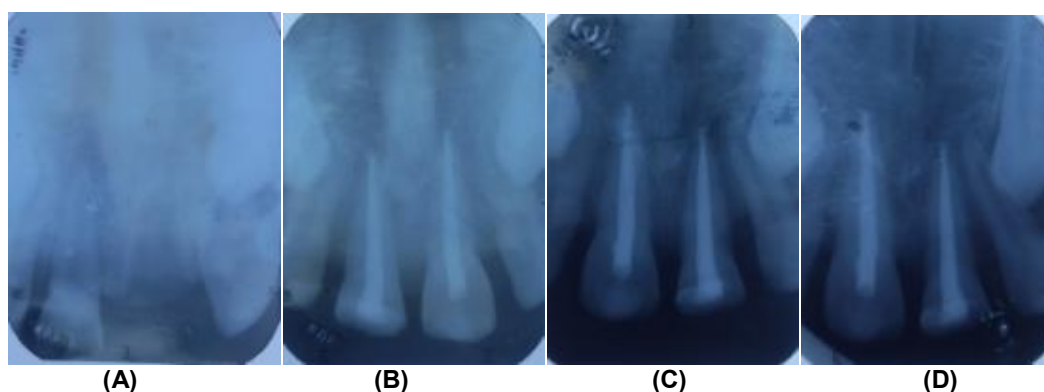
Study found that mature teeth in children and adolescents exhibit more extensive inflammatory root resorption after replantation compared to adult [13]. The mentioned increase root resorption rate is related to the bone remodelling which is more extensive in children during the grow-up period. The root resorption ankylosis may give rise to infraocclusion during the growing process [13]. Either prosthetic replacement of the missing incisors, or prosthetic implant placement might be alternative treatment options for our presented case, if replantation were not practicable. However, both of the options need time for complete root formation of the abutments as well as adequate bony thickness of implant. In this aspect, the period of sustainability of replanted teeth bears utmost importance.



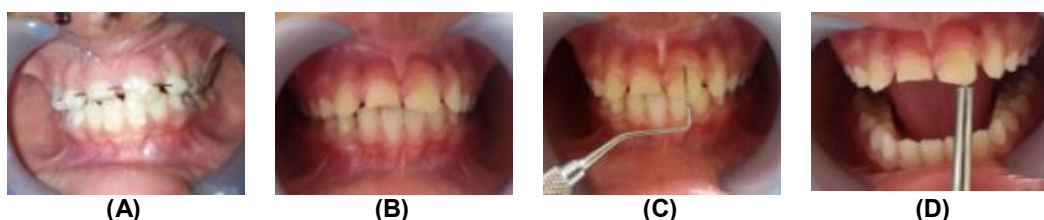**Fig. 1. Intraoral photograph showing immediate after reported to dentist (A), removal of clot and debris from the alveolar socket (B), immediate placing the tooth to corresponding socket (C), to evaluate the occlusal relationship (D)**



**Fig. 2. The avulsed tooth at saline before endodontic procedure(A), access cavity preparation (B), extirpation of pulp (C) and endodontic obturation by lateral condensation (D)**



**Fig. 3. Periapical radiographic evaluation of the socket area immediate after reporting to dentist (A), 10 post replantation after removal of bonded wire (B), at six months recall visit (C) and at one year recall visit (D)**



**Fig. 4. Post treatment intraoral photograph on the 10 days recall visit after management (A), immediate after removal of bonded wire (B), checking of periodontal pocket at 6 months recall visit (C), checking of functional at one year recall visit (D)**

The knocked out teeth can maintained aesthetic and functional properties for some years after the replantation. In this report, the replanted teeth remained in a stable functional position during 12 months follow-up period without any sign of ankylosis or resorption. Despite the positive results observed after 1 year, clinical and radiographic follow-up of the teeth also planned for further follow up. As such injuries are not uncommon, in the developing country like Bangladesh where advance materials and infrastructure is not available, following such management protocol with basic technique could save million.

#### 4. CONCLUSION

Amount of damage to tooth and supporting structures, emergency treatment and follow-up period play a role in the prognosis of knocked out teeth. It can be recommended to keep that teeth in a suitable solution and treatment started as early as possible. According to the findings of the presented case, replantation can be advised for avulsed teeth with prolong extra oral time, but risk of resorption at long time should be considered.

## CONSENT

All authors declare that 'written informed consent was obtained from the patient's mother (as patient is 12-years-old) for publication of this case report and accompanying images.

## ETHICAL APPROVAL

It is not applicable.

## COMPETING INTERESTS

Authors have declared that no competing interests exist.

## REFERENCES

1. Chadwick BL, White DA, Morris AJ, Evans D, Pitts NB. Non-carious tooth conditions in children in the UK, British Dental Journal. 2006;200:379-84.
2. Andreasen JO, Andreasen FM. Avulsions In Textbook and color atlas of traumatic injuries to the teeth, ed. 4<sup>th</sup> Andreasen JO, Andreasen FM, Andersson L. Blackwell Munksgaard, Copenhagen. 2007;444-88.
3. Chowdhury SS, Howlader MR. RE-plantation of accidentally avulsed tooth: A case report. J. Bangladesh Coll Phys. Surg. 2013;31:39-44.
4. Andresen JO, Borum MK, Andresen FM. Replantation of 400 avulsed permanent incisors. 4. Factors related to periodontal ligament healing. Endod Dent Traumatol. 1995;11(2):76-89.
5. Blomlof L, Otteskog P, Hammarstrom L. Effect of storage in media with different ion strengths and osmolarities on human periodontal ligament cells. Scand J. Dent Res. 1981;89(2):180-7.
6. Siglas E, Regan JD, Kramer PR, Witherspoon DE, Opperman LA. Survival of human periodontal ligament cells in media proposed for transport of avulsed teeth. Dent Traumatol. 2004;20(1):21-8.
7. Hiltz J, Trope M. Vitality of human lip fibroblasts in milk, Hanks balanced salt solution and viaspan storage media. Endod Dent Traumatol. 1991;7(2):69-72.
8. Blomlof L. Milk and saliva as possible storage media for traumatically exarticulated teeth prior to replantation. Swed Dent J. Suppl. 1981;8:1-26.
9. Trope M, Friedman S. Periodontal healing of replanted dog teeth stored in viaspan, milk and Hanks Balanced Salt Solution. Endod Dent Traumatol. 1992;8:183-88.
10. Elinevid H, Jansson L, Lindsog S, Weintraub A, Blomlof L. Endodontic pathogens: Propagation of infection through patent dentinal tubules in traumatized monkey teeth. Endod Dent Traumatol. 1995;11(5):229-34.
11. Ingle JI, Bakland LK, Baumgartner JC. Ingle's endodontics. 6<sup>th</sup> ed. Hamilton, Ontario: BC Decker Inc. 2008;1348-51.
12. Sae-Lim V, Wang CY, Trope M. Effect of systemic tetracycline and amoxicillin on inflammatory root resorption of replanted dogs' teeth. Endod Dent Traumatol. 1998;14(5):216-20.
13. Ebelesender KA, Freihs S, Ruda C, Perl C, Glockner K, Hulla H. A study of replanted permanent teeth in different age groups. Endod Dent Trumatol. 1998;14: 274-8.

© 2015 Chowdhury et al.; This is an Open Access article distributed under the terms of the Creative Commons Attribution License (<http://creativecommons.org/licenses/by/4.0>), which permits unrestricted use, distribution and reproduction in any medium, provided the original work is properly cited.

*Peer-review history:*

*The peer review history for this paper can be accessed here:*

<http://www.sciencedomain.org/review-history.php?iid=1118&id=12&aid=9169>