



Impact of Prophylactic Bilateral Central Lymph Nodes Dissection in Patients with Papillary Thyroid Carcinoma; Short Term Outcome

**Mohammed Farid Elhelbawy^{1*}, Ahmed Elgendy¹,
Abd El-Wahhab Hemedah Gad¹ and Ahmed Attia Darwish¹**

¹*General Surgery Department, Faculty of Medicine, Tanta University, Tanta, Egypt.*

Authors' contributions

This work was carried out in collaboration among all authors. Author MFE designed the study, performed the statistical analysis, wrote the protocol and wrote the first draft of the manuscript. Authors AE and AEWHG managed the analyses of the study. Author AAD managed the literature searches. All authors read and approved the final manuscript.

Article Information

DOI: 10.9734/JAMMR/2020/v32i1630625

Editor(s):

(1) Dr. Emin Umit Bagriacik, Gazi University, Turkey.

Reviewers:

(1) Pratyay Pratim Datta, Kotshila Rural Hospital, India.

(2) Shailja Chatterjee, Yamuna Institute of Dental Sciences and Research, India.

Complete Peer review History: <http://www.sdiarticle4.com/review-history/61019>

Original Research Article

Received 01 July 2020

Accepted 05 September 2020

Published 12 September 2020

ABSTRACT

Background: Papillary thyroid carcinoma is the most common thyroid carcinoma. There is a debate on prophylactic removal of central lymph nodes. Some authors advise it to avoid recurrence while other investigators condemn it due to its higher risk of recurrent laryngeal nerve injury and/or hypoparathyroidism.

Aim of the Work: The aim of this study was to evaluate the safety and morbidity of central lymph nodes dissection during total thyroidectomy in the management of patients with papillary thyroid carcinoma.

Patients and Methods: Twelve patients were confirmed by histopathological evaluation to have papillary thyroid examination. Total thyroidectomy was done through transverse neck incision followed by removal of bilateral central group of lymph nodes. Patients were examined postoperatively for recurrent laryngeal nerve injury or hypoparathyroidism. Follow up was done 6 months later with neck ultrasonography, thyroglobulin and antithyroglobulin antibodies.

Results: Thirty four percent of the studied cases proved to have lymph nodes metastasis. temporary hypocalcemia occurred in only one patient in this study and was temporary. Recurrent

*Corresponding author: E-mail: mohammed.elhelbawy@med.tanta.edu.eg;

laryngeal nerve affection happened in 17% of the studied cases and was reversible by medical treatment. No evidence of recurrence happened in the first 6 months after operation.

Conclusion: The risk of postoperative recurrent laryngeal nerve injury or hypoparathyroidism is minimal after prophylactic CLND. Postoperative hypocalcemia and recurrent laryngeal nerve injury are usually reversible.

Keywords: Central lymph nodes; hypocalcemia; recurrent laryngeal nerve; papillary thyroid carcinoma.

1. INTRODUCTION

THYROID CANCER is the commonest malignancy of endocrine glands. The most common type of thyroid carcinomas is papillary thyroid carcinoma (PTC) representing about 80-85% of cases with excellent prognosis having 10 year survival rates exceeding 90% [1].

Total thyroidectomy is widely accepted as the treatment of choice for patients with lesions more than 10 mm in diameter. Despite favorable prognosis, patients with PTC tend to have lymph nodes metastases in a rate of 20-50%. The most affected lymph nodes are those in the central compartment of the neck including the prelaryngeal, pretracheal and paratracheal lymph nodes(level VI) [2,3].

Physical examination and imaging studies can accurately detect metastasis in the lateral group of cervical lymph nodes giving a chance of preoperative planning of lateral neck dissection. On the other hand, imaging studies cannot precisely detect central lymph nodes metastasis from PTC [4].

Therapeutic central neck dissection (CND) is recommended in cases with PTC with clinical or radiological evidence of central lymph nodes metastasis. On the contrary, there is a debate about prophylactic removal of central group of lymph nodes in patients without any evidence of central nodal metastasis [5].

Prophylactic CND helps prevent future recurrence, reach accurate staging , decrease postoperative thyroglobulin levels. Moreover, it helps to avoid a 2nd operation in cases with recurrence [6].

Other authors deny prophylactic CND in order to decrease the risk of injury to parathyroid gland leading to subsequent hypoparathyroidism or injury to recurrent laryngeal nerve without any

demonstrable benefits in the terms of long term survival [7].

2. PATIENTS AND METHODS

Twelve patients were included in this prospective study. They were operated on by the surgical oncology team at General Surgery Department of Tanta University Hospitals during the period from January 2019 to December 2019.

2.1 Inclusion Criteria

Patients proved cytologically to have PTC with without clinically palpable central cervical lymph nodes.

2.2 Exclusion Criteria

1. Patients with simple goiter.
2. Patients with non papillary thyroid carcinoma.
3. Patients with thyroid lymphoma.
4. Patient with clinically palpable central lymph nodes.

2.3 Preoperative Workup

Every patient was subjected to:

- 1- History taking: Age, sex, occupation, special habits, reducibility, duration.
- 2- Examination:
 - **General:** Vital data (blood pressure, pulse and temperature) and general condition
 - **Local:** For detection of the lesion and assessment for presence of any central lymph nodes metastasis.
- 3- **Investigations:**
 - **Laboratory:** Routine laboratory investigations as: Complete blood analysis, renal function tests and other

investigations of assessment of thyroid function (free T3, free T4, TSH, thyroglobulin and antithyroglobulin antibodies).

- **Imaging:** Neck ultrasound: to report on the size, consistency, echogenicity, infiltration of the surroundings and evaluate cervical lymph nodes involvement.
- **Fine needle aspiration cytology (FNAC):** To confirm the pathological nature of the disease and immunohistochemistry studies.
- **Preoperative laryngoscopy:** To report on vocal cord status.

2.4 Patient Preparation

Prophylactic antibiotics: 1 gm of (Amoxicillin + clavulanic acid) IV was given half an hour before induction of anaesthesia.

2.5 Operative Details [8]

Operations were performed under general anesthesia with the patients in supine position with full neck extension. Skin disinfection was done with 10% povidone iodine antiseptic solution.

Collar incision 2 fingers above sternal notch, extending to anterior borders of both sternocleidomastoid muscles. Platysma is incised with electro-cautery avoiding injury to anterior jugular vein and when injury is unavoidable the vein is ligated between ligatures. Dissection is done creating upper and lower flaps with the upper flap till just above the upper border of thyroid cartilage and the lower flap to the sternal notch.

Strap muscles were separated from each other in midline and retracted laterally. The adjacent strap muscles and the associated adventitial tissues are swept away from the thyroid lobe and retracted laterally and gland is dissected for middle thyroid vein which is ligated and divided.

Superior vessels are then ligated within the upper thyroid pole to avoid injury to external laryngeal nerve, then upper pole is caught between arterial clamps and remaining stump of

it was transfixed. Inferior thyroid vessels are ligated & divided as closer as possible to the gland (capsular dissection).

Recurrent laryngeal nerve is identified to avoid its injury. Recurrent laryngeal nerve runs parallel to trachea and turn obliquely into larynx. On medial rotation of thyroid lobes it appears oblique anteromedially in its course. Both superior and inferior parathyroid gland are identified and preserved from being avulsed or devascularized during dissection.

After lifting the thyroid gland from its bed, Central lymph nodes, prelaryngeal, pretracheal and paratracheal were removed leaving the trachea bare. (Fig. 1)

A suction drain is placed to be exited from the lateral end of the wound. Closure of strap muscles and platysma muscle was done with absorbable sutures (vicryl 2/0), then closure of skin by continuous subcuticular sutures using non absorbable (prolene 4/0). Before extubation, the anaesthetist is asked to report on mobility of vocal cords.

The excised thyroid gland and central group of lymph nodes were then sent for histopathological examination.

2.6 Postoperative Care

In the immediate postoperative period, assessment of voice and breathing to detect injury in the recurrent laryngeal nerve was done. For detection of postoperative hypocalcemia, measuring serum calcium and parathormone level was done 6 hours after operation. The drain is left for 48 hours after operation. If it drains more than 50 cc, it is left in place.

2.7 Follow Up

Six months after the operation every patient was subjected to:

A-laboratory workup in the form of:

- Parathormone level
- Thyroglobulin
- Antithyroglobulin antibodies

B-Neck ultrasonography.

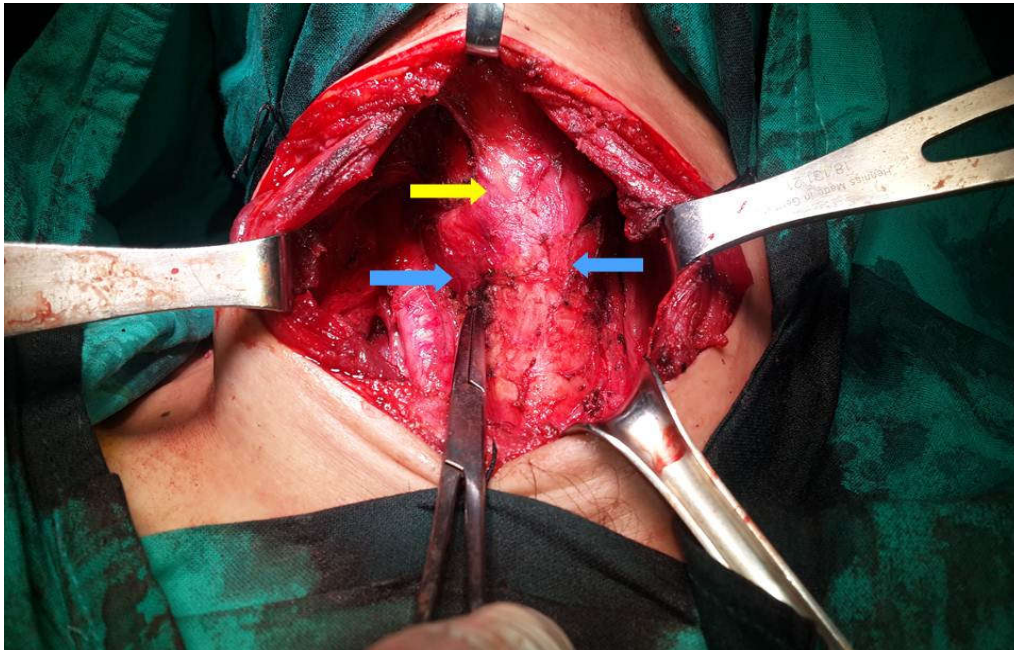


Fig. 1. A picture showing an empty bed of the thyroid gland after prophylactic removal of the central group of lymph nodes with blue arrows showing bare trachea and yellow arrow showing the larynx

3. RESULTS

This is a prospective study including 12 adult patients diagnosed as papillary thyroid carcinoma. They were operated on by the surgical oncology team at General Surgery Department in Tanta University Hospital during the period from January 2019 till December 2019.

The demographic data, surgical history and comorbidities of patients in this study are illustrated in (Table 1).

Preoperative ultrasound revealed hypoechoic nodules in eight patients and isoechoic nodules in 4 cases. On the other hand, US guided FNAC was conclusive for papillary thyroid carcinoma in seven patients whereas, four patients had atypical follicular aspirate in FNAC study. One patient presenting with lateral neck swelling had her FNAC results as a branchial cyst. After excision of the swelling it revealed a branchial cyst with areas of papillary thyroid carcinoma after which total thyroidectomy with prophylactic bilateral central lymph nodes dissection was done. (Fig. 2) Another patient with atypical follicular aspirate underwent hemithyroidectomy after which paraffin sections were done revealing PTC. This patient was subjected to a 2nd

operation for completion thyroidectomy and prophylactic bilateral CND.

Table 1. The demographic data of the studied cases

Table 1	No.	%
Age (years)		
30 – 40	6	50.0
40 – 50	3	25.0
50 – 60	2	16.7
60 – 70	1	8.3
Sex		
Male	2	16.7
Female	10	83.3
Medical history		
Free	9	75.0
DM	2	16.7
HTN	1	8.3

Central lymph nodes dissection did not evidently increase the operative time with a mean duration of 9.42 minutes.

Regarding the excised central group of lymph nodes, eight of patients showed reactive central group of lymph nodes (66.7%) while the remaining four patients proved malignant central group of lymph nodes (33.3%).

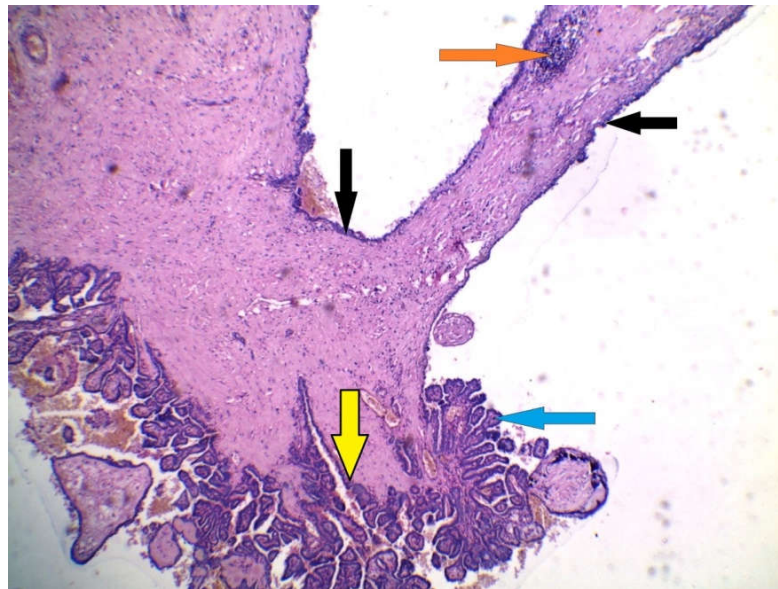


Fig. 2. A picture shows a case of branchial cyst with papillary thyroid carcinoma showing normal cyst lining (black arrows) with lymphoid follicle in the wall (orange arrow). Some areas showed multiple papillae formation (blue arrow) infiltrating the cyst wall (yellow arrow). (H&E X40)

3.1 Postoperative Complications

3.1.1 Recurrent laryngeal nerve injury

Two patients (16.7%) had temporary affection of vocal cords; one of them developed stridor after extubation where otolaryngologist was invited into the operative theatre for tracheostomy. This patient had one fixed vocal cord preoperatively. The patient was given iv steroids (dexamethasone ampule) every 12 hours for the first 2 days, thereafter, she was discharged on oral steroids (prednisone 5 mg tab twice daily) and vitamin B12 injections twice weekly. Reassessment of vocal cord mobility one month later revealed one cord regained mobility and tracheostomy tube was removed.

The other patient had some sort of hoarseness and after postoperative assessment one vocal cord was fixed and the other was mobile and she was given oral steroids (prednisone tablets) for 3 weeks and vitamin B12 intramuscular injections every one week together with oral vitamin b complex tablets. Over five weeks she regained normal voice and mobility of vocal cords on reassessment by laryngoscopy. (Table 2)

3.1.2 Hypocalcemia

None of the studied cases developed permanent hypoparathyroidism while only one patient (8.3%)

developed symptoms of hypocalcemia in the form of perioral numbness and carpedal spasm in the second day after operation with serum ionized calcium level 0.95mmol/l. She was given iv calcium gluconate. Then the patient was started on calcium carbonate oral tablets 2 times daily and vit D (alpha calcidol) capsules and she was discharged four days later. Serum calcium was measured in weekly follow up visits and oral supplementation could be stopped one month after operation. The patient was encouraged to have calcium containing meals like milk and milk products. (Table 3)

Table 2. Postoperative vocal cords assessment

Recurrent laryngeal nerve affection	No.	%
Temporary		
No affection	10	83.3
Stridor	1	8.3
Hoarseness of voice	1	8.3
Permanent	0	0.0

Table 3. Postoperative calcium level

Hypocalcemia	No.	%
Temporary		
Normal level	11	91.7
Evident hypocalcemia	1	8.3
Permanent	0	0.0

3.2 Follow Up

All patients in this study were given a radioactive iodine dose one month after the operation by medical oncologists.

Every patient was followed up 6 months after operation for recurrence by:

- a- Assessment of thyroglobulin level which revealed athyroglobulinemia in all patients (100%) with serum thyroglobulin less than 1.4 ng/ml. (Table 4)
- b- Assessment of antithyroglobulin antibodies which revealed 9 of the studied cases (75%) decreased more than 50% of preoperative values while 3 of cases (25%) decreased less than 50% of preoperative values. (Table 4)
- c- Neck U/S which revealed no evidence of local recurrence

Table 4. Six months postoperative antithyroglobulin antibodies level

	No	%
Anti thyroglobulin antibodies level 6 months postoperatively		
Decreased more than 50%of preoperative value		75%
Decrease less than 50% of preoperative value		25%

4. DISCUSSION

This study was designed to assess the impact of prophylactic CLND as a further procedure to total thyroidectomy in patients with PTC.

Most of the studied cases in this study were females (83.3%). This agrees with the findings of Alvarado et al. [9] and Moo et al. [10] who reported that the female predominance in their studies was 83% and 77% respectively.

In the studied cases, the age of patients ranged from 31 to 70 years. Out of them, fifty percent were 30 to 40 years with a mean age 45 years. Similar findings were reported by Alvarado et al. [9] and Moo et al. [10]. On the other hand, relatively older age groups were documented by Pereira et al. [11] with a mean age of 52.2.

In the present study, sixty six (66%) percent of cases showed the presence of hypoechoic nodules compared to relatively higher incidence in finding of hypoechoic nodules in other studies

by Jun et al. [12] who reported 78% incidence and Chan et al. [13] who reported 86% incidence of hypoechoic nodules in their studies. While calcification existed in US imaging of 50% of cases in this study. Similar incidence of calcification was reported by Chan et al. [13] with a 53% incidence of calcification. However, relatively lower incidence of calcification was found with Yuan et al. [14] who reported calcifications in 40% of their studied cases. Calcification in papillary thyroid carcinoma is attributed to the presence of psammoma bodies.

In this study, fine needle aspiration cytology in the studied cases was conclusive for papillary thyroid carcinoma in 58.3% while 33.3% showed atypical aspirate and 8.3% showed non thyroid pathology. Wu et al. [15] reported papillary thyroid carcinoma in only 30% of their studied cases. The relatively higher conclusive value of FNAC in our study may be attributed to the use of immunohistochemistry. Haymart et al. [16] used intraoperative frozen section technique in order to avoid the inconclusive results of FNAC. Frozen section revealed papillary thyroid carcinoma in 87% of cases who initially proved suspicious by FNAC. This proves how valuable intraoperative frozen section is so as to avoid a 2nd operation.

Temporary postoperative hypocalcemia, with serum ionized calcium level less than 1.05mmol/l, occurred in 8.3% of the studied patients. Relatively higher incidence was reported by Alvarado et al. [9] and Moo et al. [17] who reported 11% and 17% incidence of postoperative temporary hypocalcemia respectively. On the other hand, there were no cases of permanent hypoparathyroidism in the studied cases. This low rate of hypocalcemia can be due to the small number of cases in the present study on one hand. Furthermore, we were keen to preserve the parathyroid gland intraoperatively.

Out of the studied cases, 16.6% showed evidence of injury of recurrent laryngeal nerve in the immediate postoperative period in the form of temporary vocal cord dysfunction which resolved later on with steroids and neurotonics. Moo et al. [17] and Moo et al. [10] showed relatively lower incidence of temporary postoperative vocal cord dysfunction 8.9% and 5% respectively. None of the studied cases developed postoperative permanent injury of the recurrent laryngeal nerve. This relatively higher incidence of temporary vocal cord dysfunction in our study

maybe due the small number of cases in this study besides one patient in this study had already a fixed vocal cord on one side preoperatively.

After postoperative histopathological evaluation of the excised lymph nodes, 33.3% of excised lymph nodes proved to be positive for malignant cells. Wang et al. [18] and Kutler et al. [19] reported malignant deposits in 41% and 40% of their studied cases respectively.

Follow up of patients in studied cases was done after 6 months of surgery by clinical, laboratory and ultrasound assessment which revealed no evidence of local recurrence. Moo et al. [10] reported a lower incidence of recurrence in patients undergoing total thyroidectomy with central lymph nodes dissection (4.4%) compared to those patients undergoing thyroidectomy alone (16.7%). Zhao et al. [20] also showed reduced recurrence rates in patients who are subjected to central lymph nodes dissection with thyroidectomy (4.6%) compared to patients subjected to total thyroidectomy alone who had 6.9% recurrence rates. There is no evidence in literature about a certain time for recurrence but most studies followed up patients for at least 2 years which means follow up for longer duration for patients in this study is recommended.

5. CONCLUSION AND RECOMMENDATIONS

From this study we conclude that sensitivity of ultrasonography in diagnosis of papillary thyroid carcinoma is nearly 70% which means removal and histopathological evaluation is the best to reach diagnosis. Moreover, FNAC is also not reliable in the diagnosis of papillary thyroid carcinoma. Immunohistochemistry studies are essential to avoid the inconclusive result of FNAC. Prophylactic central lymph nodes dissection helps to decrease incidence of recurrence in PTC. This study also showed that bilateral central lymph nodes dissection does not evidently increase the operative time. The risk of postoperative hypoparathyroidism or recurrent laryngeal nerve injury are comparable to cases who undergo total thyroidectomy alone. In addition, hypocalcemia and recurrent laryngeal nerve injury in most cases are reversible. Consequently, we recommend that prophylactic CLND should be done in all cases with PTC in order to avoid recurrence. Moreover, intraoperative frozen section is useful for confirmation of histopathological nature of thyroid

nodules in cases showing equivocal results in FNAC so as to avoid a 2nd operation. Our study should be followed up for 2 years and we recommend a bigger number of cases for future studies.

CONSENT AND ETHICAL APPROVAL

The details of the operation technique and complications were explained to the patient and an informed written consent was obtained. Approval by the ethical committee for research in Tanta Faculty of medicine was obtained before initiating this study.

COMPETING INTERESTS

Authors have declared that no competing interests exist.

REFERENCES

1. Siegel RL, Miller KD, Jemal A. Cancer statistics. CA: A Cancer Journal for Clinicians. 2016;66(1):7–30.
2. Fagin JA, Wells Jr.SA. Biologic and clinical perspectives on thyroid cancer. New England Journal of Medicine. 2016; 375(11):1054-1067.
3. Alvarado R, Sywak MS, Delbridge L, Sidhu SB. Central lymph node dissection as a secondary procedure for papillary thyroid cancer: Is there added morbidity? Surgery. 2009;145(5):514–518.
4. Barczyński M, Konturek A, Stopa M, Nowak W. Prophylactic central neck dissection for papillary thyroid cancer. British Journal of Surgery. 2013;100(3): 410-418.
5. Wang TS, Cheung K, Farrokhyar F, Roman SA, Sosa JA. A meta-analysis of the effect of prophylactic central compartment neck dissection on locoregional recurrence rates in patients with papillary thyroid cancer. Annals of Surgical Oncology Journal. 2013;20(11): 3477–3483.
6. Carty SE, Cooper DS, Doherty GM, Duh QY, Kloos RT, Mandel SJ, et al. Consensus statement on the terminology and classification of central neck dissection for thyroid cancer. Thyroid Journal. 2009; 19(11):1153–1158.
7. Pereira JA, Jimeno J, Miquel J, Iglesias M, Munne´ A, Sancho JJ. Nodal yield, morbidity, and recurrence after central neck dissection for papillary thyroid

- carcinoma. *Surgery*. 2005;138(6):1095–1101.
8. Clark OH, Duh QY, Kebebew E. Thyroidectomy–Standard (28) in *Textbook of Endocrine Surgery*. 3rd edition, Jaypee Brothers Medical Publisher, California, USA. 2016;339-358.
 9. Alvarado R, Sywak MS, Delbridge L, Sidhu SB. Central lymph node dissection as a secondary procedure for papillary thyroid cancer: Is there added morbidity? *Surgery*. 2009;145(5):514-518.
 10. Moo TA, McGill J, Allendorf J, Lee J, Fahey T, Zarnegar R. Impact of prophylactic central neck lymph node dissection on early recurrence in papillary thyroid carcinoma. *World Journal of Surgery*. 2010;34(6):1187-119.
 11. Pereira JA, Jimeno J, Miquel J, Iglesias M, Munné A, Sancho JJ, et al. Nodal yield, morbidity, and recurrence after central neck dissection for papillary thyroid carcinoma. *Surgery*. 2005;138(6):1095-1101.
 12. Jun P, Chow LC, Jeffrey RB. The sonographic features of papillary thyroid carcinomas: Pictorial essay. *Ultrasound Quarterly*. 2005;21(1):39-45.
 13. Chan BK, Desser TS, McDougall IR, Weigel RJ, Jeffrey JrRB. Common and uncommon sonographic features of papillary thyroid carcinoma. *Journal of Ultrasound in Medicine*. 2003;22(10):1083-1090.
 14. Yuan WH, Chiou HJ, Chou YH, Hsu HC, Tiu CM, Cheng CY, et al. Gray-scale and color doppler ultrasonographic manifestations of papillary thyroid carcinoma: Analysis of 51 cases. *Clinical Imaging*. 2006;30(6):394-401.
 15. Wu HHJ, Jones JN, Grzybicki DM, Elsheikh TM. Sensitive cytologic criteria for the identification of follicular variant of papillary thyroid carcinoma in fine-needle aspiration biopsy. *Diagnostic cytopathology*. 2003;29(5):262-266.
 16. Haymart MR, Greenblatt DY, Elson DF, Chen H. The role of intraoperative frozen section if suspicious for papillary thyroid cancer. *Thyroid*. 2008;18(4):419-423.
 17. Moo TAS, Umunna B, Kato M, Butriago D, Kundel A, Lee JA, et al. Ipsilateral versus bilateral central neck lymph node dissection in papillary thyroid carcinoma. *Annals of surgery*. 2009;250(3):403-408.
 18. Wang TS, Evans DB, Fareau GG, Carroll T, Yen TW. Effect of prophylactic central compartment neck dissection on serum thyroglobulin and recommendations for adjuvant radioactive iodine in patients with differentiated thyroid cancer. *Annals of Surgical Oncology*. 2012;19(13):4217-4222.
 19. Kutler DI, Crummey AD, Kuhel WI. Routine central compartment lymph node dissection for patients with papillary thyroid carcinoma. *Head & neck*. 2012;34(2):260-263.
 20. Zhao W, You L, Hou X, Chen S, Ren X, Chen G, et al. The effect of prophylactic central neck dissection on locoregional recurrence in papillary thyroid cancer after total thyroidectomy: A systematic review and meta-analysis. *Annals of Surgical Oncology*. 2017;24(8):2189-2198.

© 2020 Elhelbawy et al.; This is an Open Access article distributed under the terms of the Creative Commons Attribution License (<http://creativecommons.org/licenses/by/4.0>), which permits unrestricted use, distribution, and reproduction in any medium, provided the original work is properly cited.

Peer-review history:

The peer review history for this paper can be accessed here:

<http://www.sdiarticle4.com/review-history/61019>