



## **A Rare Entity of Desmoid Tumour: A Review**

**Yash Bhagwat <sup>a\*</sup> and Anup Kediya <sup>b<sup>o</sup></sup>**

<sup>a</sup> *Jawaharlal Nehru Medical College, Datta Meghe Institute of Medical Sciences, Sawangi (M), Wardha, Maharashtra, India.*

<sup>b</sup> *Department of Pathology, Jawaharlal Nehru Medical College, Datta Meghe Institute of Medical Sciences, Sawangi (M), Wardha, Maharashtra, India.*

### **Authors' contributions**

*This work was carried out in collaboration between both authors. Both authors read and approved the final manuscript.*

### **Article Information**

DOI: 10.9734/JPRI/2021/v33i61B35129

### **Open Peer Review History:**

This journal follows the Advanced Open Peer Review policy. Identity of the Reviewers, Editor(s) and additional Reviewers, peer review comments, different versions of the manuscript, comments of the editors, etc are available here: <https://www.sdiarticle5.com/review-history/80317>

**Review Article**

**Received 24 October 2021**  
**Accepted 27 December 2021**  
**Published 28 December 2021**

## **ABSTRACT**

Desmoid tumors are a rare monoclonal, fibrotic boom characterized by a variable and conventional scientific course. Desmoids are invasive and related to a high clot recurrence rate and no longer have cancerous activity. Desmoids are identified with the valuable resource of changes in the  $\beta$ -catenin gene A.P.C.

There are many troubles regarding the appropriate cure for victims with desmoid tumors. Rema the debate still; the surgical cure is the clinical way, without multiplying and related with significant attribute loss.

Therefore, the software of a multifunctional examination with multimodality therapy sorts the foundation of care for these patients. Waiting possibly be the most fabulous administration in some asymptomatic patients

Patients with desmoids positioned at the mesentery or head and neck should showcase life-threatening troubles and choose more excellent aggressive therapy. This evaluation article describes cure preferences and administration techniques for sufferers with desmoid tumors with a middle of interest on advanced disease.

Postoperative radiotherapy reduces the nearby recurrence rate in situations of worried surgical margins. Because of the heterogeneity of the biological behavior of desmoids, including prolonged periods of constant ailment or spontaneous regression, therapy desires to be individualized to

<sup>≡</sup>MBBS Student;

<sup>o</sup>Professor;

\*Corresponding author: E-mail: o10443.jnmc@dmimsu.edu.in;

optimize nearby tumors to manipulate and retain patients' exceptional of life. Desmoids are hence an amazing uncommon tumor thing. Desmoids manifest between the age of 15 and 60 years. Still, in unique at some factor of late puberty, along with the maximum age of 30 yrs. 2 different kinds of desmoid tumors are shown. Except for spreading desmoid tumor occurrence, there is a high-quality relation of desmoids...It can be related to the potential of persistent liver tissue damage and contamination accompanied by the beneficial aid of liver resuscitation. Meiotically lively liver cells, covered thru another environment, is most probable susceptible to hereditary stability is lost, and most cancers development.

*Keywords: Beta-catenin; Tumour markers; fibrosis.*

## 1. INTRODUCTION

Clonality in tumors may be examined o hereditary girls for unique X-linked pointers due to random X inactivation effects in all women having parts from 2o cellular values. So, often many girls will have each group of enzymes; however, inform that a single life-threatening marker is expressed.

The encoding of B protein seems to disturb the increased use of contaminated hepatocytes every day via turning on some essential genes. Hex again motives suppress the tumor suppressor gene, i.e., p53 [1]. The consequences in B leading to liver cell carcinoma. Desmoids are invasive and related to a higher close recurrence rate and no longer have cancerous activity. Desmoids are identified with the valuable resource of changes occurs of  $\beta$ -catenin gene A.P.C [2].

The period desmoid tumor explains a fibrotic growth disease.

In its biological behavior is categorized into:

1. Nonharmful fibrotic tissue growth
2. sarcoma

Desmoid tumors concerning WHO are described as "clonal fibrotic growths that origin in inner hard cells and are characterized with the resource of infiltrative boom and a regional revival as an incapacity to spread "[3]. Desmoid tumors perchance affect all sites, which include the arms legs, abdomens, etc. Just 9% of spreading desmoid tumors is inside the abdomen, 70% of sufferers by hereditary adenomatous polyposis (.H.A.P.)-related desmoid tumors enhance intraabdominal condition. An occurrence is clean cell cancer, about 1.12% of every cancerous.

Desmoids are hence an amazing uncommon tumor thing. Desmoids manifest between the age

of 15 and 60 years. Still, in unique at some factor of late puberty, along with the maximum age of 30 yrs. 2 different kinds of desmoid tumors are shown. Except for spreading desmoid tumor occurrence, there is a high-quality relation between desmoids and AP [4].

Low-grade fibro myxoid sarcoma may be reliably marked out using the detection of unique translocations which involve the FUS-CREB3L2 gene. Gardner fibroma is an uncommon neoplasm in men and women. Having diseases in the intestinal cocci gene, A.P.C., in the more excellent arm of chromosome 5 thick take place in the same places [5].

Primary therapy or victims having domestically dissected desmoid tumors stays surgical division. The remark would possibly be a choice from a band of people. The increased sample of the tumors is very severe; tumor capsules are absent [6]. Due to the borders in the tumors ais tough to Difficult inside the tumor from wounds and cells, the R0 intersection is no longer continually plausible, and adjacent radiation is consequently regularly utilized following the cancer procedures.

On the other hand, Desmoids has huge regional revival fee post-surgical technique or radiation or showcase swift proliferation. The base can often take multiple repetitions and many focus doses and, consequently, is now not amenable to recovery surgical therapy. DNA restore function and inhibit cell cycle checkpoints activated with the resource of DNA damage. These make contributions to increased possibilities of most cancers through the potential of the capability of HTLV-1 [7].

In this situation, pharmacotherapy is frequently used to cause ailment progression.

Some differential assessment of intra-abdominal fibrosis consists of gastrointestinal stromal tumor,

solitary fibrosis tumor (SFT), inflammatory myofibroblast tumor (I.M.T.), sclerosing mesenteritis, and retroperitoneal fibrosis (maybe necrotic [Orimond condition] and side effect to some capsules or hidden cancer, like a lymph tumor). Nowadays, the presence of abdomen-based desmoids with GSTs was once shown. The different prognosis in desmoid-kind of fibrosis of large, in fibrotic cancers in a tone of the extremes and comparable fibrotic and myofibroblast figures, for example, nodular fasciitis and also hypertrophic marks and keloids in other places [8]. The remark would be possibly a choice from a band of people.

The most crucial intention was to keep the persons' style of living, the is scattered using the function loss and suffering prompted with means of using growth disease. Clinical techniques for remedy of external or internal desmoid tumors consists of:

1. Without hormonal therapy
2. Nonsteroidal anti-inflammatory capsules
3. standard chemotherapy procedures

It has no longer been feasible to set up a splendid remedy procedure for this condition. on the other hand, many comparisons of victims with desmoid tumors are maintained, and remedy strategies perchance consist of surgical procedures and radioactive and antigrowth therapy [9]. The following evaluation describes attainable therapy alternatives and handling strategies for sufferers of desmoid tumors, the center of interest on the highest quality condition.

## 2. CLINICAL CHARACTERISTICS

One scientific route in desmoid tumors is strange and heterogeneous, characterized solely by tumor growth, growth, and disorder progression but through stabilization and even sudden occurrence. Due to the bouders in the tumors ais tough to Difficult inside the tumor from wounds and cells, the R0 intersection is no longer continually plausible, and adjacent radiation is consequently regularly utilized following the cancer procedures [10].

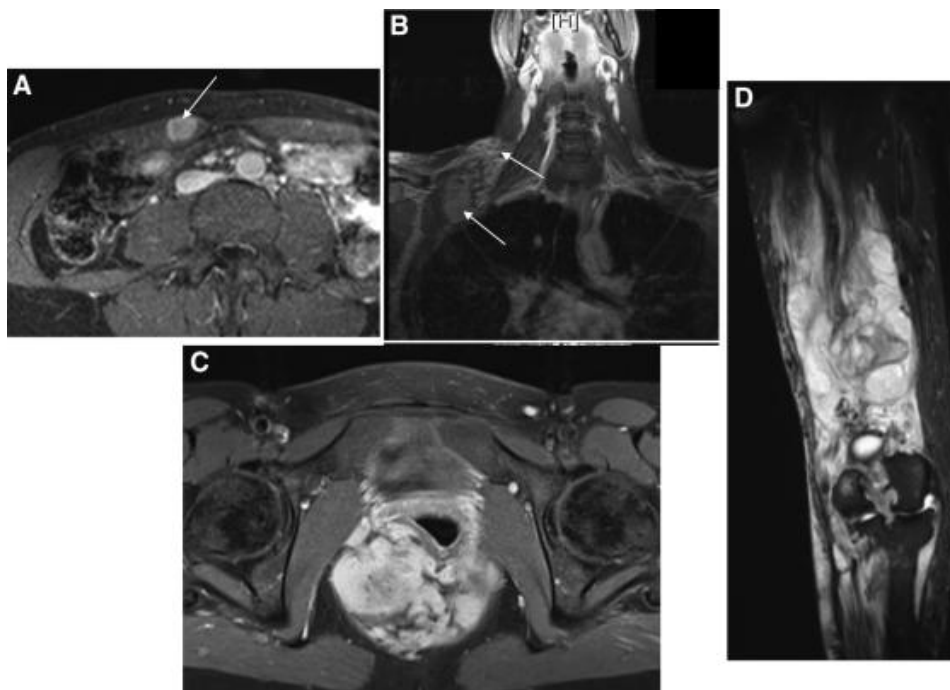
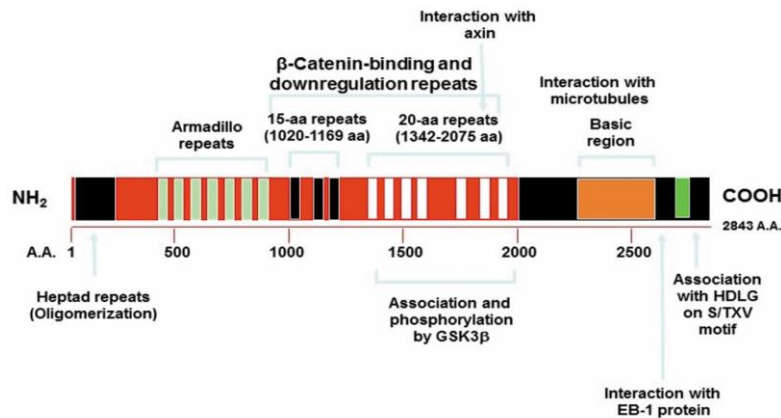


Fig. 1.

- (A) Pregnancy-related desmoid located in Rectuse abdominal muscle  
(B) Multiple external desmoid achieving above the leg to the popliteal depression in the person struggling from with a predisposing condition  
(C) Desmoid seen in the lower pelvis, preventing vaginal delivery  
(D) External, desmoid located skull, and cervical vertebrae place down to the superior chest wall and plexus of brachial.



**Fig. 2. Pathogenesis**

Segregation saw in the undifferentiated cancerous tumors: At times, several tumors like plastic, lymphoma, melanoma, sarcoma are hard to differentiate with regular H n E marking due to lousy differentiation. So, immunochemical reactants may assist the diagnosis.

**Example**

- Occurrence of cytokeratin factors to epithelial cancer.
- occurrence in Desmin if precise for muscle cell origin.
- occurrence of WBC usual Antigen factors of lymph node tumors

1. Searching of starting place of cancerous tumors: markers are available that are a factor of the entry of tumors located in the biological sample in the metastasis. E.g., it consists of prostate cancer and cancer of the thyroid [11].
2. Prognostic or clinical significance Estrogen or estradiol site detection is the clinical fee in breast cancers. Positive marked breast cancers are inclined to anti-estrogen therapy. Congruently, over-use in Erb-B2 gene signs to the terrible diagnosis

**2.1 HTLV-1**

The RNA cancerous virus is transferred through the RBCs and plasma, transfusion, and breastfeeding. There is the enchantment of CD4 T cells. HTLV-1 consists of a protein TAX. A tax gene Q leads to:

1. Translation in human genes concerned in growth or segregation in B-tissue (F.O.S., Interleukin two genes)

2. Hereditary weakness with the valuable resource of inhibiting DNA restore function and using inhibiting cell-cycle checkpoints activated with the resource of DNA damage. These contribute to increased possibilities of most cancers through the potential of capability HTLV-1.

**2.2 H.C.V.**

Hepatitis C virus is additionally highly related to an improvement of hepatocellular cancer. It can be related to the potential of persistent liver tissue damage and contamination accompanied by the beneficial aid of liver resuscitation. Meiotically lively liver cells, covered thru another environment, is most probable susceptible to hereditary stability is lost, and most cancers development.

**2.3 HBV**

The encoding of B protein seems to disturb the everyday increase use of contaminated hepatocytes via turning on for some essential genes. Hex again motives suppress the tumor suppressor gene, i.e., p53. The consequences in B lead to liver cell carcinoma.

**3. DIFFERENTIAL DIAGNOSIS**

The different prognosis in desmoid-kind fibrosis of large, fibrotic cancers is in a tone of the extremes and relative fibrotic and myofibroblast figures, such as nodular fasciitis and hypertrophic marks and keloids in other places. The remark would possibly be a choice from a band of people. The increased sample of the tumors is very severe; tumor capsules are absent. Due to the bourders in the tumors ais

tough to Difficult inside the tumor from wounds and cells, the R0 intersection is no longer continually plausible, and adjacent radiation is consequently regularly utilized following the cancer procedures.

### 3.1 Extra Abdominal Fibromatosis

Fibrotic sarcoma is a positive result seen of  $\beta$ -catenin staining, but usually is greater cellular, has more significant cases of atypia, and the spindle cells exhibit a herring-bone-like pattern.

Low-grade fibro myxoid sarcoma may be reliably marked out by detecting unique translocations involving the FUS–CREB3L2 gene. Gardner fibroma is an uncommon neoplasm in men and women having diseases in the intestinal cocci gene, A.P.C., in the more excellent arm of chromosome 5, which occurs in the same places. There is a greater chance of fibrosis in the cases of the tropical area in the people staying in the humid and moist atmosphere. The stromal cells, like these of desmoid tumors, the transcriptional role of  $\beta$ -catenin is considered crucial. The  $\beta$ -catenin phosphorylation used a component of the protein encoded using exon three of CTNB1, the gene encoding  $\beta$ -catenin.

Both lesions exhibit nuclear expression of  $\beta$ -catenin in a massive percentage. In contrast to desmoid-type fibroma, Gardner fibroma indicates much less cellularity and a more significant amount of collagen, and the spindle cells categorical CD34.

Low-grade fibro myxoid sarcoma presents a smaller and more fragile organelle that usually

has curvilinear vessel walls. The  $\beta$ -catenin result is positive in thirty percent of people. Radioactive-related morbidity and mistakes, radioactive treatment must be avoided in cases of negative tumor margins, except for patients with large desmoids with difficulty continuing cases of revival. According to decreased use of limited therapeutic trials, there is mainly very debate regarding the appropriate administration of systemic therapy for advanced disease. Medical therapy, consisting of antihormonal therapy and NSAIDs, looks helpful with a relative hardness.

### 3.2 Intra-abdominal Fibrosis

Some differential assessment of intra-abdominal fibrosis consists of gastrointestinal stromal tumor, solitary fibrosis tumor (SFT), inflammatory myofibroblast tumor (I.M.T.), sclerosing mesenteritis, and retroperitoneal fibrosis (maybe necrotic [Orimond condition]and side effect to some capsules or hidden cancer, like a lymph tumor).

Desmoid tumors concerning WHO are described as “clonal fibrotic growths that origin is the hard inner cell and are characterized with the resource of infiltrative boom and a regional revival as an incapacity to spread” Desmoid tumors perchance affect all sites, which include the arms, legs, abdomens, etc. Just 9% of spreading desmoid tumors is inside the abdomen, 70% of sufferers by hereditary adenomatous polyposis (H.A.P.)-related desmoid tumors enhance intraabdominal condition. An occurrence is clean cell cancers, about 1.12% of every cancerous.

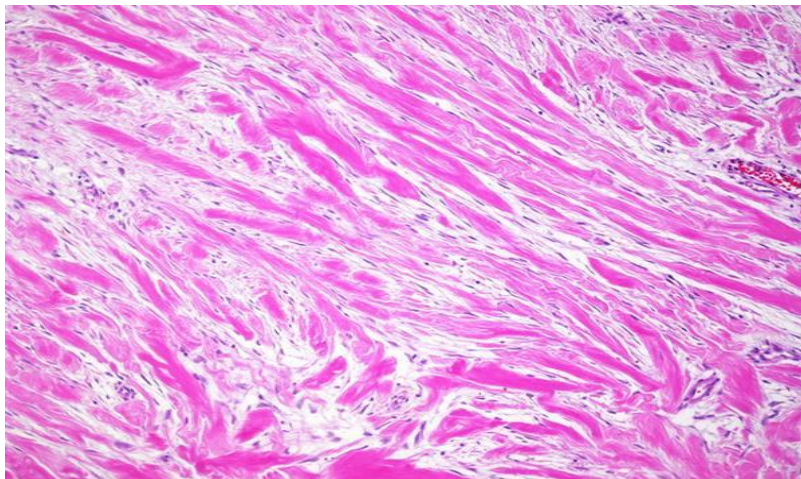
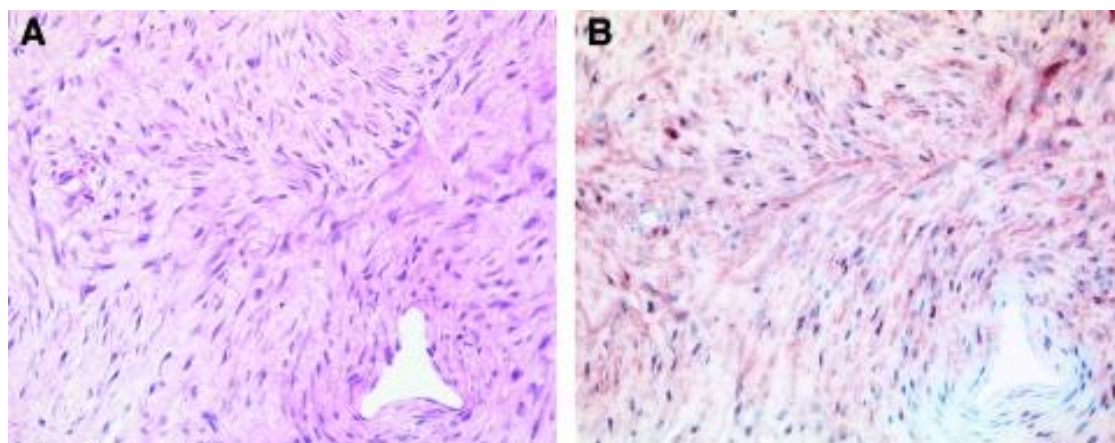


Fig. 3. Abdominal Fibromatosis



**Fig. 4. Histopathology**

Nowadays, the presence of abdomen based desmoids with GSTs were once shown.

### 3.3 Function of Beta-catenin

The molecule  $\beta$ -catenin is given two roles cutaneous cells, living as small sticking molecules or in the translation tools in the nucleus. The stromal cells, like these of desmoid tumors, the transcriptional role of  $\beta$ -catenin is considered crucial. The  $\beta$ -catenin phosphorylation is used by a protein component encoded using exon three of CTNB1, the gene encoding  $\beta$ -catenin.

Surgery has usually been the clinical way for mainly respectable; small size desired tumor people. On the other hand, due to the changes in the therapeutic doses, the importance of the place of disease, the use, and the application of therapeutics procedures has been intensely discussed.

In co-existence in germline and bodily changes on some patients, A.P.C. of the desmoid tumors has presented. Changes of RAAS genes and p53 gene are typically not observed in diamonds; for this reason, inactivation of each copy in the A.P.C. PROTEIN is concerned with some improvement of desmoid tumors.

## 4. THERAPY METHODS

Surgery has usually been the clinical way for mainly respectable, small, desmoid tumors. On the other hand, due to the changes of the therapeutic do theses and the importance of the place of disease, therapeutics procedures have been intensely discussed. The use of the micro

condition of tumor boundaries is incredibly complicated. Few alternative types of research found that microscopically positive margins were clearer of a more considerable recurrence speed.

No data is found from any company testings “tumor-rectory” having approval boundary cuts in serious tumor removal targeted for R0 division. Hepatocellular cancer. It can be related to the potential of persistent liver tissue damage and contamination accompanied by the beneficial aid of liver resuscitation. Meiotically lively liver cells, covered thru another environment, is most probable susceptible to hereditary stability is lost, and most cancers development.

### 4.1 Radiotherapy

Radiotherapy was applied in the controlled conditions post-surgery, local conditions, and extra-abdominal tumors.

The relapse rate dropped from 70% to 15% when radiation therapy was added after operation for patients with positive margins after surgery. The result was noted for both primary and recurrent desmoid tumors

#### Therapy Methods for Advance Stages

Antihormonal therapy in therapy of desmoid tumors is made over findings of the fundamental nature of the condition. Specific observations, for example, higher incidences of desmoids during and after pregnancy and reports of spontaneous tumor regression after menopause, form the basis for antihormonal therapy. Studies have shown that virtually all desmoid tumors express

nuclear estrogen site- $\beta$ , but only a small subset of patients respond to antihormonal therapies.

The use of NSAIDs for excessive applied on the surprising observation of total decrease of one desmoid tumor in the person's breastbone having in do- methane of radioactive –caused disease. Desmoid tumors are a rare monoclonal, fibrotic tumor characterized by a variable and conventional scientific course. Desmoids are invasive and related to a higher close recurrence rate and no longer have cancerous activity. Desmoids are identified with the valuable resource of changes of  $\beta$ -catenin gene A.P.C. Due to playing a part in detecting desmoid tumors, therapy with NSAIDs that inhibit COX may be effective. Moreover, NSAIDs shows on the  $\beta$ -catenin process.

Locoregional chemotom, the way of the different leg or arm fusion, is another way of overall chemotherapy in patients with limb desmoids, which is particularly interesting if one considers that desmoid tumors unusual form of cancer. Melphalan and tryptophan tumor apoptosis gene -cis engaged as clinical agents along with total reactive forms of almost 70. Alternatively, intratumorally more vessels disa on more transfer rather rapidly; however, it perhaps appears several weeks to months until a partial or complete response forms. This technique looks very helpful for patients with small progressive or extreme tumors not used to operations.

Summarization

Desmoid tumors are an unusual and hereditary disease that requires personal therapy to decrease the risk for small tumors.

Targets for personalized therapy must decrease mortality and loss of function and preserve patient life. Several things in the correct therapy of patients with desmoid tumors remain debated. On the other hand, adequate surgical dissection from negative boundaries is the treatment of favor except when surgery is mutilating and related with significant loss of function or significant morbidity. With people having, chemotherapy is indicated and dramatically decreases the low rate after the operation [12,13].

Due to radioactive-related morbidity and mistakes, radioactive treatment must be avoided in cases of negative tumor margins, except for patients with large desmoids with difficulty

continuing cases of revival. According to decreased use of limited therapeutic trials, the mainly very debate regarding the appropriate administration of systemic therapy for advanced disease. Medical therapy, consisting of antihormonal therapy and NSAIDs, looks to be helpful with a relative harness.

## 5. CONCLUSION

Desmoid tumors are a rare monoclonal, fibrotic tumor characterized by a variable and conventional scientific course. Desmoids are invasive and related to an extreme close by recurrence rate and no longer have cancerous activity. Several things in the correct therapy of patients with desmoid tumors remain debated. On the other hand, adequate surgical dissection from negative boundaries is the treatment of favor except when surgery is mutilating and related with significant loss of function or significant morbidity.

## DISCLAIMER

The products used for this research are commonly and predominantly used in our research area and country. There is no conflict of interest between the authors and producers of the products because we do not intend to use these products as an avenue for litigation but for the advancement of knowledge. Also, the research was not funded by the producing company rather it was funded by personal efforts of the authors.

## CONSENT

It is not applicable.

## ETHICAL APPROVAL

It is not applicable.

## COMPETING INTERESTS

Authors have declared that no competing interests exist.

## REFERENCES

1. Biermann JS. Desmoid tumourss. *Curr Treat Options Oncol.* 2000;1:262-266. [PubMed]
2. Seegenschmiedt MH German Cooperative Group on Radiotherapy for Nonharmful

- Diseases. Radiation therapy for aggressive fibromatosis (desmoid tumours): Results of a national Patterns of Care Study. *Int J Radiat Oncol Biol Phys.* 2005;61:882–891. [PubMed]
3. Bertario L, Russo A, Sala P, et al. Hereditary Colorectal Tumours Registry. Multiple approaches to the exploration of genotype-phenotype correlations in familial adenomatous polyposis. *J Clin Oncol.* 2003;21:1698–1707. [PubMed]
  4. Clark SK, Phillips RK. Desmoids in familial adenomatous polyposis. *Br J Surg.* 1996;83:1494-1504.
  5. Janinis J, Patriki M, Vini L, et al. The pharmacological treatment of aggressive fibromatosis: A systematic review. *Ann Oncol.* 2003;14:181–190.
  6. Pignatti G, Barbanti-Bròdano G, Ferrari D, et al. Extraabdominal desmoid tumor. A study of 83 cases. *Clin Orthop Relat Res.* 2000;(375):207–213.
  7. Knudsen AL, Bülow S. Desmoid tumour in familial adenomatous polyposis. A review of literature. *Fam Cancer.* 2001;1:111–119.
  8. Casali PG, Blay JY. Esmo/Conticanet/Eurobonet Consensus Panel of Experts. Soft tissue sarcomas: ESMO clinical practice guidelines for diagnosis, treatment and follow-up. *Ann Oncol.* 2010;21(suppl 5):v198–v203.
  9. Okuno S. The enigma of desmoid tumors. *Curr Treat Options Oncol.* 2006;7:438–443.
  10. Stoeckle E, Coindre JM, Longy M, et al. A critical analysis of treatment strategies in desmoid tumours: A review of a series of 106 cases. *Eur J Surg Oncol.* 2009;35:129–134.
  11. Carlson JW, Fletcher CD. Immunohistochemistry for beta-catenin in the differential diagnosis of spindle cell lesions: Analysis of a series and review of the literature. *Histopathology.* 2007;51:509–514.
  12. Jaiswal NK, Kediya A, Makrande J. Desmoid Tumour - A Rare Entity. *Journal of Evolution of Medical and Dental Sciences-JEMDS.* 2021;10(3):170–2.
  13. Varma AD, Dhande RP, Pattabiraman S. Abdominal Wall Desmoid Tumour Diagnosis on CT Scan-A Case Report. *Journal of Evolution of Medical and Dental Sciences-JEMDS.* 2021;10(3):153–5.

© 2021 Bhagwat and Kediya; This is an Open Access article distributed under the terms of the Creative Commons Attribution License (<http://creativecommons.org/licenses/by/4.0>), which permits unrestricted use, distribution, and reproduction in any medium, provided the original work is properly cited.

*Peer-review history:*

*The peer review history for this paper can be accessed here:*  
<https://www.sdiarticle5.com/review-history/80317>